

# Double independent pedicle oncoplastic mammoplasty: a technique for breast preservation

*Mamoplastia oncoplástica com duplo pedículo independente: uma técnica para a preservação mamária*

Régis Resende Paulinelli<sup>1</sup>, Eneida Ribeiro Marinho<sup>2</sup>

## Keywords

Breast neoplasms  
Breast  
Surgery  
Mammoplasty  
Reconstruction  
Plastic Surgery  
Reconstructive surgical procedures  
Breast diseases

## Descritores

Neoplasias mamárias  
Mama  
Cirurgia  
Mamoplastia  
Reconstrução  
Cirurgia plástica  
Procedimentos de reconstrução cirúrgica  
Doenças mamárias

## ABSTRACT

**Introduction:** This study describes a new means of oncoplastic mammoplasty named the double independent pedicle method. **Patients and methods:** Between October 2008 and August 2011, eight patients with upper-quadrant tumors of unfavorable proportions were included after signing an informed consent form. The tumors were excised with a macroscopic 2 cm margin. The areola was kept vascularized with a medial or lateral pedicle. An extensive infero-central pedicle was constructed to fill the defect. Metal clips were emplaced to guide radiotherapy. The contralateral breast symmetry was corrected. **Results:** The patients' mean age was 49.00 years ( $\pm 12.59$ ). Mean tumor size was 44.25 mm ( $\pm 18.25$  mm). The median preoperative ptosis was grade 2 (range: 1–3), and it was corrected in all cases. The physician's assessment (from 0 to 10) for breast shape and symmetry was 9.13 ( $\pm 1.46$ ). All the patients said they were more satisfied with breast shape after surgery. A medial pedicle was chosen in 50% of the cases. Invasive ductal carcinoma was the most common tumor. There was one benign case of pseudoangiomatous hyperplasia. One patient presented a voluminous hematoma, which evolved with partial dehiscence of the suture. There was one case of mild partial areola necrosis. All tumors were resected with free margins, but two patients (25%) underwent mastectomy and reconstruction after the postoperative discovery of multicenter tumors. There was no fat necrosis or recurrence over a period of 26.13 ( $\pm 11.01$ ) months of follow-up. **Conclusions:** The technique enabled breast conservation in unfavorable situations, with ptosis correction.

## RESUMO

**Introdução:** Este estudo descreve uma nova técnica de mamoplastia oncoplástica chamada duplo pedículo independente. **Pacientes e métodos:** Entre outubro de 2008 e agosto de 2011, oito pacientes com tumores de quadrantes superiores, de proporções desfavoráveis para a conservação, foram incluídos após assinarem um termo de consentimento informado. Os tumores foram excisados com margens macroscópicas de 2 cm. A areola foi mantida vascularizada com um pedículo medial ou lateral. Um pedículo infero-central extenso foi confeccionado para reconstruir o defeito. Clips metálicos foram colocados para guiar a radioterapia. A mama contralateral foi simetrizada. **Resultados:** A média da idade das pacientes foi 49,00 anos ( $\pm 12,59$ ). A média do tamanho do tumor foi de 44,25 mm ( $\pm 18,25$  mm). A mediana da ptose preoperatória foi grau 2 (1–3) e foi corrigida em todos os casos. A nota dada pelo médico (de 0 a 10) para a forma mamária e a simetria foi de 9,13 ( $\pm 1,46$ ). Todas as pacientes disseram estar mais satisfeitas com o formato da mama após a cirurgia. O pedículo medial foi escolhido em 50% dos casos. O carcinoma ductal invasor foi o tumor mais frequente. Havia um caso de tumor benigno, hiperplasia pseudoangiomatosa. Uma paciente apresentou um hematoma volumoso, que evoluiu

<sup>1</sup>Staff at the Mastology Program of the Department of Gynecology and Obstetrics at Universidade Federal de Goiás (UFG) – Goiânia (GO), Brazil.

<sup>2</sup>Staff at the Institute of Mastology and Oncology – Goiânia (GO), Brazil.

Correspondence: Régis Resende Paulinelli – Alameda Americana do Brasil, 282, apto 801, Setor Marista – CEP 74180-010 – Goiânia (GO), Brazil – E-mail: rrpaulinelli@gmail.com

Received on: 10/31/2012. Accepted on: 11/14/2012.

*com deiscência parcial da sutura. Houve um caso de uma pequena necrose parcial da areola. Todos os tumores foram ressecados com margens livres, mas duas pacientes (25%) foram submetidas à mastectomia e reconstrução após a descoberta posoperatória de tumores multicêntricos. Não houve casos de necrose gordurosa ou recorrência no período de 26,13 ( $\pm 11,01$ ) meses de seguimento. **Conclusões:** A técnica possibilitou a conservação mamária em situações desfavoráveis e a correção da ptose.*

## Introduction

Conservative treatment for breast cancer presents a cure rate similar to that achieved by mastectomy, provided that disease-free margins can be obtained<sup>1,2</sup>. However, depending on the relationship between the sizes of tumor and breast, poor aesthetic results may be obtained. Oncoplastic mammoplasty may enable the resection of larger areas of the breast, with improvement of surgical margins, prevention of deformities and improvement of the aesthetic result, by the correction of asymmetries and ptosis<sup>3,4</sup>.

Tumor resection in lower or central quadrants is relatively easy and widely disseminated. Therefore, conventional mammoplasty techniques are used, with superior pedicles<sup>5</sup>. In such cases, the tumor tends to be in the area usually resected in mammoplasty procedures. Likewise, the areola can be removed and subsequently reconstructed, in cases of central tumors<sup>6</sup>.

However, the most malignant breast tumors are located in the upper quadrants. For these tumors, techniques in which the areola remains attached to an inferior pedicle can be used<sup>7,8</sup>. However, this technique has been criticized because of the possibility of partial recurrence of ptosis, and because it does not provide good correction in cases of tumors located far from the areola. There are also other possibilities, such as rotation, shutter, round block and bilobed flap techniques, among others, which enable the resection of larger lesions in the upper quadrants, but do not allow ptosis correction so easily<sup>4,9,10</sup>.

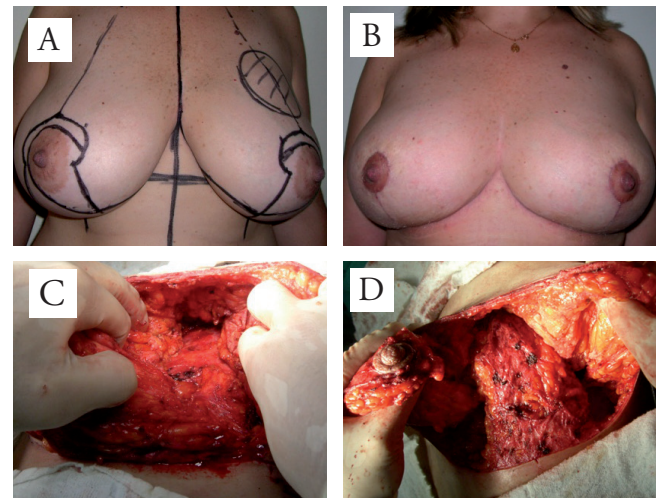
Even with the already existing oncoplastic techniques, many patients undergo mastectomy with reconstruction because of the impossibility to obtain good aesthetic and oncological results with conservative treatment. No matter how good the reconstruction is, the reconstructed breast does not have the same naturalness and sensitivity as the original breast in patients who undergo oncoplastic mammoplasty<sup>11</sup>.

Aiming to extend the indications of oncoplastic mammoplasty and decreasing the need for mastectomy with reconstruction, we developed a new type of mammoplasty using two independent pedicles: one for the areola (medial or lateral pedicle) and another to correct the oncological defect (extensive inferocentral pedicle). This leads to good access to tumors in the upper quadrants, even if distant from the areola. In this study, we present our initial experience with this technique.

## Materials and methods

Between October 2008 and August 2011, eight patients were included (Figures 1 to 8). They presented relatively voluminous tumors in relation to breast size, which were located in the upper quadrants. The possibility of a good aesthetic result for breast conservation in these cases was low, even with usual oncoplastic techniques. The patients were properly told that the proposed treatment consisted of an alternative, a modified oncoplastic mammoplasty technique, in the attempt to enable breast conservation and ptosis correction. All the patients agreed to undergo the procedure and signed an informed consent form. The principles outlined in the Declaration of Helsinki have been followed. Oncologic and reconstructive surgeries were both performed by the same breast surgeon, who had been trained in breast oncoplastic surgery.

All patients underwent routine preoperative examinations (blood cell count, fasting blood glucose, coagulogram and electrocardiogram). Surgical risk was assessed and additional examinations were requested for patients with other diseases, such as hypertension, heart diseases

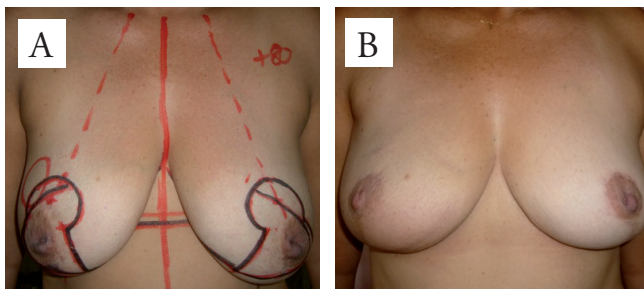


**Figure 1.** A 37-year-old patient with an 8-cm malignant phyllodes tumor at the boundaries of the breast, in the upper quadrants. (A) shows the preoperative marking; (B) the postoperative result, four months later; (C) the defect from the quadrantectomy; (D) the positioning of the inferocentral pedicle so as to fill the defect due to the quadrantectomy, and the pedunculated areola medially

etc. All patients underwent percutaneous histological core biopsy of the tumor before surgery. They all underwent prior mammography and breast ultrasonography for surgical planning, and two of them also had magnetic resonance imaging. The examinations performed for breast cancer staging were: TGO, TGP, bilirubin, DHL, alkaline phosphatase, ultrasonography of the upper abdomen and chest radiography. Immunohistochemical analysis was requested for all core biopsy fragments, and this was repeated on the surgical specimens when they were negative for hormone receptors or HER2.

### Preoperative marking

The preoperative marking followed the pattern of inverted-T reduction mammoplasty. It was performed with the patient standing up and the surgeon sitting down, so that the patients' breasts were at the surgeon's eye level. First, the median line was marked from the manubriosternal joint passing through the xiphoid process and going as far as the umbilical scar. Afterwards, the inframammary fold was marked bilaterally. A paramedian line was then defined starting from the inframammary crease and going caudally, in the region corresponding to the projection of the nipple. This line was located 9 to 11 cm from the median line, depending on the dimensions of the breast and chest.



**Figure 2.** A 46-year-old patient with mixed lobular and ductal tumor, measuring 4 cm before neoadjuvant chemotherapy and 3 cm after it, in the lateral upper quadrant of the right breast. (A) the preoperative marking; (B) the postoperative appearance two years after surgery

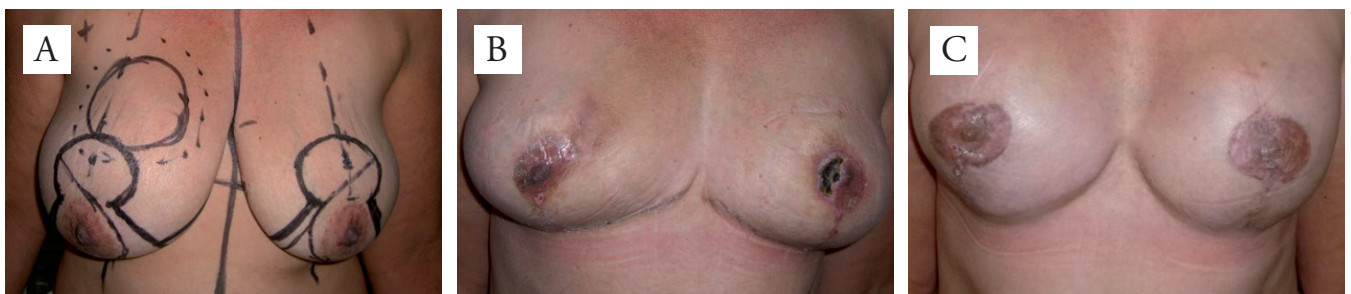We marked a line starting 4 cm from the jugular notch, going from the clavicle to the nipple. Point A, corresponding to the new position of the nipple, was set by placing a finger below the breast and gently raising the inframammary crease, following the line marked previously (Figure 9A). The upper edge of the areola was located 2 cm above point A.

The area of the new areola was defined with an oval shape of diameter 7 cm in the transverse plane and 5 cm in the parasagittal plane, on average. These dimensions could vary a few centimeters, according to the surgeon's subjective assessment, depending on the excess skin to be resected and the preoperative diameters of the areola (Figure 9B). By gently rotating the breast superolaterally and superomedially, the vertical excess skin to be resected was marked with a line going from point A to the inframammary line, corresponding to the projection of the areola (Figures 9C and D).

It was very important not to resect too much skin, which might have resulted in suture tension. In cases of doubt, it was better to mark the lines slightly closer and resect additional skin later on, during the surgery, after confirming there was no excessive tension.

Points B and C were marked on this line, 4.5 to 7 cm from the outline of the areola, depending on the desired size of the new breast. The transverse excess skin was marked by gently rotating the breast, first superolaterally and then superomedially, until points B and C became aligned with the inframammary crease, thus delimiting the skin to be sutured in the inframammary crease. The medial or lateral pedicle, according to the location of the tumor, was marked as a curve going from the limits of the new position of the areola, passing through point A and around the edge of the areola with a 2 cm margin, and as far as point B in the case of a medial pedicle, or point C in the case of a lateral pedicle. The contralateral breast was marked similarly.

The tumor area was defined similarly to that macroscopic surgical margin of 2 cm. An independent extensive inferocentral pedicle was designed to cover the defect from the quadrantectomy, so that the size of the base would be at



**Figure 3.** A 49-year-old patient with a 6-cm malignant phyllodes tumor in the medial upper quadrant of the right breast. (A) the preoperative marking; (B) the postoperative appearance, 20 days later, showing partial necrosis of the left areola. The patient underwent bilateral mastectomy because multiple foci of *in situ* and invasive lobular carcinoma were detected bilaterally. These were only found through anatomopathological examination on the breast reduction areas. (C) the result after exchanging the expanders and reconstructing the areola-nipple complex using a C-V flap and microdermal pigmentation

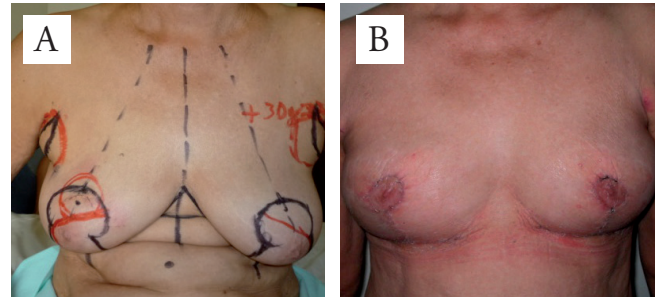
least two thirds of the length. On the contralateral breast, another independent short inferior pedicle was marked in order to achieve symmetry in terms of breast projection.

### Surgical technique

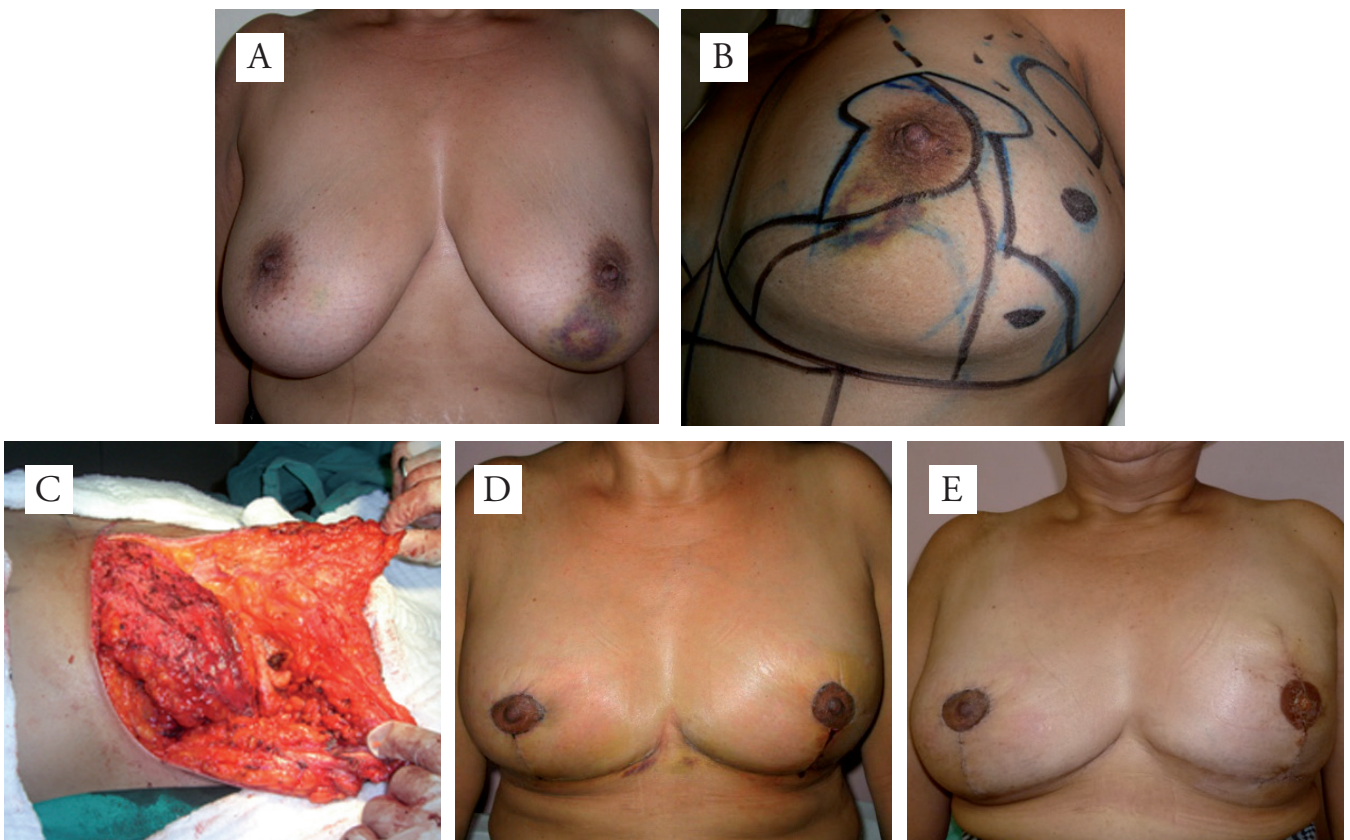
The procedure was carried out with the patient in dorsal decubitus, under general or thoracic epidural anesthesia, with the arms extended in order to form a cross. With the skin stretched, periareolar pressure was applied with an areolotome around the areola. Afterwards, deepithelialization of the medial or lateral pedicle and the inferior pedicle was performed. The remainder of the breast tissue encompassed in the preoperative plan was resected or incorporated into the pedicles, depending on the wanted final breast size.

The tumors were excised with an intraoperative 2 cm macroscopic margin, at least, while preferably preserving the adjacent skin when allowed by the distance to the tumor (Figure 1B). In the only case in which the skin above the tumor was resected, this preoperative marked measurement was not considered in order to enable the correct positioning of the areola.

The areola was kept vascularized by means of a medial or lateral pedicle 1 to 2 cm thick, depending on tumor location, thus enabling better access to the upper quadrants (Figure 1C). For tumors in the lateral upper quadrant or at the limit between the upper quadrants, we chose to use a medial pedicle. For tumors in the medial upper quadrant, we preferred to use a lateral pedicle. To compensate for the tissue loss in the upper quadrants, an extensive modified



**Figure 5.** A 66-year-old patient with bilateral axillary accessory breasts and 3-cm invasive ductal carcinoma at the limit between the upper quadrants of the right breast. (A) the preoperative marking; and (B) the postoperative appearance, two months later



**Figure 4.** A 51-year-old patient with 3-cm ductal invasive carcinoma in the lateral upper quadrant of the left breast, three fibroadenomas in the left breast and nine fibroadenomas in the right breast. (A) the preoperative appearance; (B) details of the preoperative marking; (C) the filling of the defect from the quadrantectomy by the infero-central pedicle; and (D) the postoperative appearance, 20 days later. Foci of multicenter high-grade *in situ* ductal carcinoma were found in the left breast through anatomopathological examination, with one of the foci inside one of the fibroadenomas. (E) shows the postoperative appearance, 20 days after exchanging the expander and reconstructing the nipple, with a C-V flap and microdermal pigmentation

inferocentral pedicle was constructed, with base width at least two thirds of the length, in order to fill the defect caused by the quadrantectomy (Figure 1D). A metal clip was emplaced to guide radiotherapy.

The margins of the surgical specimen from the quadrantectomy were marked with one dot at three o'clock, two dots at six o'clock, three dots at nine o'clock and four dots at twelve o'clock, in order to guide the pathologist. The extensive inferocentral pedicle was sutured to the remaining breast parenchyma or to the pectoralis major muscle, at the site of the quadrantectomy, so as to fill the defect (Figure 1d). The contralateral breast was made symmetrical in a similar manner.

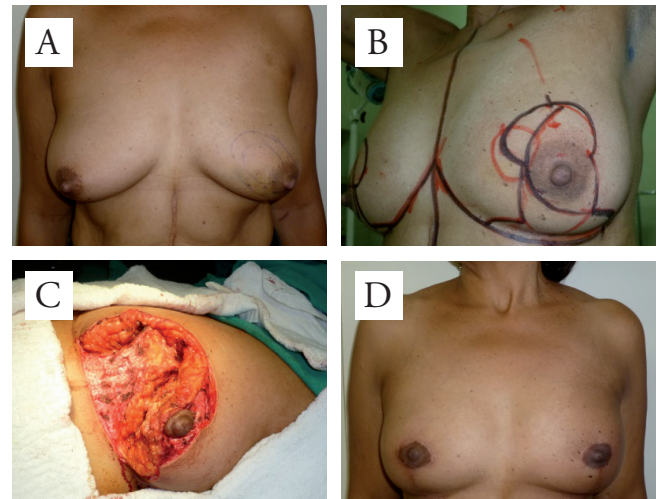
The axilla was dealt with according to the indications of the case. In clinically free armpits, we chose to perform sentinel lymph node biopsy using patent blue and/or radioactive technetium. The axilla was dissected only when clinically compromised, before neoadjuvant chemotherapy or when the axilla presented macrometastases to the sentinel lymph node.

The glandular tissue was sutured with nylon 5.0. The skin was sutured by means of simple subdermal stitches, with an inverted knot, using nylon 4.0 or 5.0 at the locations of greatest tension, and Monocryl 4.0 in the remaining areas. The intradermal suture was conducted with Monocryl 4.0, and the start and end of the suture were hidden so as to avoid the removal of stitches.

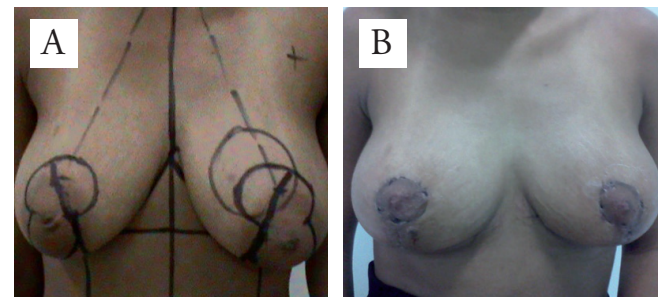
We used Portovac 4.8 drains in the breasts for one day. In the armpits, in cases of complete axillary lymphadenectomy, we used them for seven days. The patients were discharged from hospital after 24 hours, except in cases of complete axillary dissection, when we chose to discharge the patients after 48 hours.

The surgeon gave a subjective score (between zero and ten) to denote his degree of satisfaction, taking into account the shape, symmetry and ptosis of the breasts, two to six months after the surgery. The patients were also asked to give their impression regarding their breasts and to indicate their degree of satisfaction with the aesthetic result of the surgery.

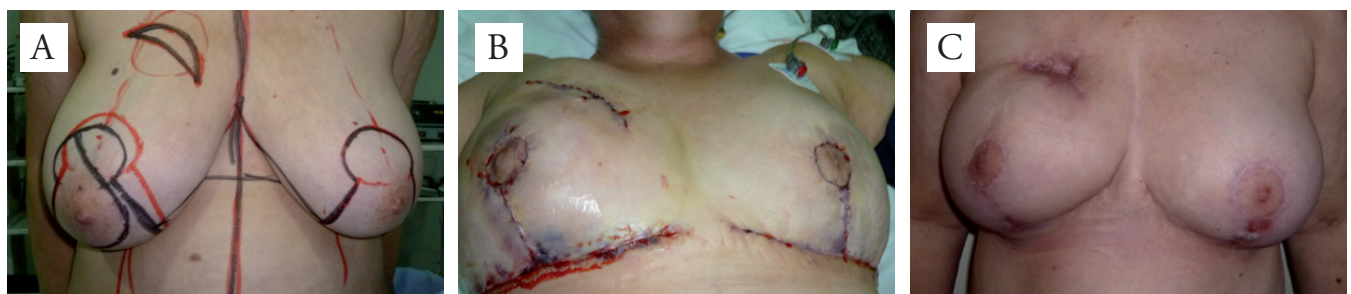The degree of breast ptosis was scored from 0 to 3, following the classification of Regnault and Bostwick. In this case, grade 0 meant the nipple and most of the mammary gland were above the inframammary crease; grade 1 showed the nipple was at the level of the crease; grade 2 meant the



**Figure 7.** A 61-year-old patient with 2.5-cm mucinous carcinoma in the medial upper quadrant of the right breast. (A) the preoperative appearance; (B) details of the preoperative marking; (C) the inferior pedicle filling the defect caused by quadrantectomy and the areola pedunculated laterally; and (D) the postoperative appearance, two months later



**Figure 8.** A 27-year-old patient with 4.5-cm pseudoangiomatous stromal hyperplasia in the medial upper quadrant of the left breast. (A) the preoperative marking; and (B) the postoperative appearance, 40 days later



**Figure 6.** A 55-year-old patient with mixed lobular and ductal tumor, measuring 4.5 cm before neoadjuvant chemotherapy and 3.5 cm after it. (A) the preoperative marking, with the new areola position marked lower, after allowing for the removal of skin close to the tumor; (B) the formation of a voluminous hematoma two days after the operation, caused by the reintroduction of anticoagulation by means of a chronic atrial fibrillation. The patient underwent reoperation for revision of the hemostasis. The patient evolved with cardiac decompensation and partial dehiscence of the sutures, bilaterally. (C) the postoperative appearance, three months after the operation, with second-intention healing still taking place, thus compromising the aesthetic result. Despite this insufficient result, the patient still felt satisfied

nipple was below the crease but above the lower outline of the breast; and grade 3 showed the nipple was below the inframammary crease and below the lower outline of the breast<sup>12</sup>.

## Results

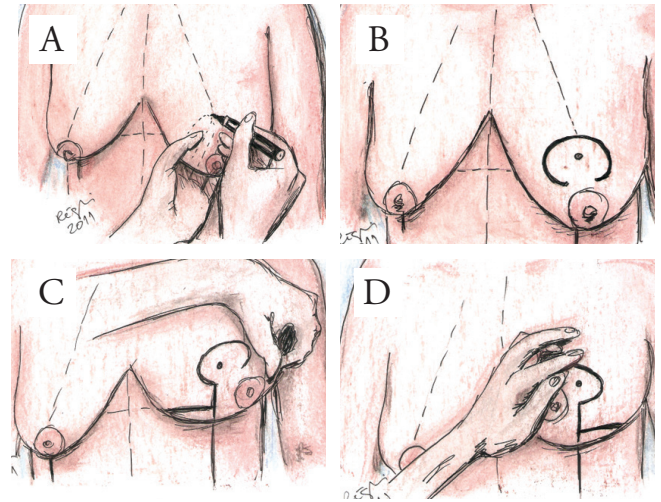
The patients' mean age was 49 years ( $\pm 12.59$ ). Five patients (62.5%) had white skin. Two of the patients (25%) had first-degree family histories of breast cancer. One (12.5%) was a smoker and three (37.5%) were hypertensive.

The mean clinical size of the tumor was 44.25 mm ( $\pm 18.25$ ), ranging from 25 to 80 mm. The estimated mean volume of the breasts was 480.63 cm<sup>3</sup> ( $\pm 193.03$ ). The mean distance from tumor to nipple was 33.75 mm ( $\pm 21.34$ ). The median grade of breast ptosis was 2 (range 1–3). The mean subjective score (between 0 and 10) given by the surgeon was 9.13 ( $\pm 1.46$ ), taking into consideration the degrees of symmetry, correction of the oncologic defect and correction of ptosis.

Four tumors (50%) were located in the medial upper quadrant; 2 (25%), in the lateral upper quadrant; and 2 (25%) at the limit between the upper quadrants. A medial pedicle was chosen in 4 cases (50%) and a lateral pedicle in the others. Invasive ductal carcinoma was the most frequent malignant tumor, accounting for 3 (42.9%) of 7 cases. There were also two cases of malignant phyllodes tumors, one of mixed carcinoma (ductal and lobular invasive) and one of mucinous carcinoma.

Histological grade 2 was most frequently found, occurring in 4 cases (50%). All the tumors presented free margins in the anatomopathological examination, but 2 patients (25%) underwent mastectomy and reconstruction using an expander and prosthesis because other foci of multicentric carcinoma were discovered in the product of breast reduction, which had been invisible in the preoperative imaging examinations (Figures 3 and 4).

Concerning complications, one patient with chronic atrial fibrillation presented a voluminous hematoma on one side, when anticoagulation was reintroduced. This case required reoperation and evolved with partial dehiscence of the suture, which compromised the aesthetic result (Figure 6). There was one case of mild partial areolar vascular sufficiency, in one patient, in which a suspicious whitish area was found close to the areola during operation. It was resected, thus leaving the lateral pedicle thinner than usual (Figure 3). This patient primarily presented a malignant phyllodes tumor, which was resected with free margins. However, the patient subsequently underwent bilateral mastectomy because multiple areas of *in situ* and invasive multicentric lobular carcinoma were found, and these had not been seen in the preoperative examinations.



**Figure 9.** Preoperative marking. (A) shows how point A is marked by placing a finger below the breast and gently raising the inframammary fold. (B) shows that the upper edge of the areola is located 2 cm above point A. The area of the new areola is marked with an average diameter of 7 by 5 cm. (C and D) show how to mark out the vertical excess skin to be resected, by gently rotating the breast superolaterally and superomedially, and tracing out a line from point A to the inframammary line corresponding to the projection of the areola. Points B and C are marked on this line, at distances of 4.5 to 7 cm from the outline of the areola, depending on the desired size of the new breast

Two patients (25%) underwent neoadjuvant chemotherapy and another 4 (50%) had adjuvant chemotherapy, according to the clinical guidance by the oncologist, including anthracyclines and taxanes. Sentinel node biopsy was performed in all six patients with invasive carcinoma, even after the two cases of neoadjuvant chemotherapy. The sentinel node was free of disease in five patients. Only one patient had a complete axillary dissection, but the sentinel node was the only metastatic one. Four patients (50%) underwent radiotherapy. The whole breast radiation therapy was fractionated, 46 Gy over 5 to 5.5 weeks, starting two months after surgery, for all the patients exclusively submitted to the conservative surgery for invasive carcinoma. Furthermore, there was the typical electron boost dose of 14 Gy, targeted to the metallic clips in the tumor bed.

Six patients (75%) used adjuvant hormone therapy and none of the patients needed to use trastuzumab. There have not been any cases of recurrence of breast ptosis, fat necrosis or tumor recurrence so far. The mean length of follow-up was 26.13 months ( $\pm 11.01$ ), ranging from 11 to 49 months.

There was one case of voluminous benign pseudoangiomatous hyperplasia, with pseudoinfiltrative growth, in a relatively small breast (Figure 8).

## Discussion

Oncoplastic surgery may provide adequate surgical margins even in many cases of voluminous tumors, with improved

aesthetic results for the breasts, thereby increasing the indications for conservative treatment<sup>13</sup>. This is simpler for tumors located in the lower quadrants, since a big proportion of the lower part is usually resected in conventional reductive mammoplasty. Although approximately 70% of malignant tumors arise in the upper quadrants, most of the tumors described in studies involving oncoplastic surgery have been in the lower quadrants<sup>5,14</sup>. The difficulty to reconstruct partial breast defects in the upper quadrants, especially in cases of lesions at a distance from the areola, led Grisotti and Calabrese to describe part of the upper quadrants as a “no man’s land”<sup>15</sup>. The new technique of mammoplasty with two independent modified pedicles enabled good access to the upper quadrants, with good correction of the oncologic defect. This took place even in some cases of small breasts, in which it was possible to remove a little more than what was necessary for the oncologic treatment. Although the fact of using double pedicles is not new for mammoplasties, it was not used exactly the same way as ours. We did not find any other description of a similar technique in literature.

One advantage of this technique in comparison with conventional surgical oncologic treatment was the improvement of the satisfaction of patients with the appearance of their breasts. This was seen in all cases because of the ptosis correction and breast asymmetry. The time a surgeon considered a result as unsatisfactory occurred because of a hematoma, which culminated in partial dehiscence of the operative wound. Even so, the patient felt satisfied with the result and did not want to undergo a new surgical procedure to correct the scar.

The complication rate with this new technique was small and within the expectation for oncoplastic mammoplasty<sup>8,16</sup>. Initially, there had been some concern about the possibility of necrosis of the deepithelialized inferocentral pedicle, due to its extensive nature. However, this did not occur in any case. We believe that using a double source of irrigation for the extended interior pedicle is safe. Our use of two sources of vascularization (inferior and central) was efficient, given that there are descriptions of mammoplasty techniques in which only one of the vascularization sources is successfully maintained<sup>8,17</sup>. Although this study mostly included cases of large tumors, for which mastectomy would usually be performed, free margins were obtained in all of them. The two patients who subsequently had to undergo mastectomy presented multifocal disease, which was discovered through the breast reduction and had not been detected by imaging methods. We only used magnetic resonance in two selected cases because of the controversies about its benefits to plan all breast conservation surgeries. Thus, these two cases of mastectomy do not represent a method limitation or a surgical failure, but the narrowness of the conventional diagnostic imaging capacity.

Follow-up is still short to assess cancer recurrence, but the main objective of this study is to evaluate the rate of free margins and the possibility of breast conservation in difficult cases, in which mastectomy would be the treatment of choice. The evidence nowadays suggests that quadrantectomy is oncologically safe whenever it is possible to achieve free margins<sup>2,4,13,18,19</sup>. Moreover, the aesthetic results and complication rates in mammoplasties tend to be stable after six months of follow-up<sup>4,20</sup>. The number of cases seems to be small, but indeed it is a quite selected group of challenging cases in which other kinds of oncoplastic breast conserving techniques would probably not apply.

In conclusion, the oncoplastic mammoplasty technique with two independent pedicles enabled breast conservation in most of the oncologically difficult situations, with ptosis correction, and also improved satisfaction and brought a reasonably low complication rate. We believe this technique can be added to the alternatives for breast oncoplastic surgery to maximize the potential of oncological surgical resection and, at the same time, to improve the aesthetic satisfaction when surgically treating benign and malignant tumors in the upper quadrants.

## References

1. Fisher B, Anderson S, Bryant J, Margolese RG, Deutsch M, Fisher ER, et al. Twenty-year follow-up of a randomized trial comparing total mastectomy, lumpectomy, and lumpectomy plus irradiation for the treatment of invasive breast cancer. *N Engl J Med.* 2002;347:1233-41.
2. Veronesi U, Cascinelli N, Mariani L, Greco M, Saccozzi R, Luini A, et al. Twenty-year follow-up of a randomized study comparing breast-conserving surgery with radical mastectomy for early breast cancer. *N Engl J Med.* 2002;347:1227-32.
3. Audretsch W, Andree C. Is mastectomy still justified - and if, in which patients? *Onkologie.* 2006;29:243-5.
4. Rietjens M, Urban CA, Rey PC, Mazzarol G, Maisonneuve P, Garusi C, et al. Long-term oncological results of breast conservative treatment with oncoplastic surgery. *Breast.* 2007;16:387-95.
5. Clough KB, Lewis JS, Couturaud B, Fitoussi A, Nos C, Falcou MC. Oncoplastic techniques allow extensive resections for breast-conserving therapy of breast carcinomas. *Ann Surg.* 2003;237:26-34.
6. McCulley SJ, Durani P, Macmillan RD. Therapeutic mammoplasty for centrally located breast tumors. *Plast Reconstr Surg.* 2006;117:366-73.
7. Azad S, Bell D, Mohammed P, Erdmann MW. Technical refinement in breast reduction using the inferior pedicle technique. *Plast Reconstr Surg.* 2002;109:2604-5.
8. Munhoz AM, Montag E, Arruda E, Aldrighi C, Filassi JR, de Barros AC, et al. Reliability of inferior dermoglandular pedicle reduction mammoplasty in reconstruction of partial mastectomy defects: surgical planning and outcome. *Breast.* 2007;16:577-89.

9. Santanelli F, Paolini G, Campanale A, Longo B, Amanti C. Modified wise-pattern reduction mammoplasty, a new tool for upper quadrantectomies: a preliminary report. *Ann Surg Oncol*. 2009;16:1122-7.
10. Lanitis S, Hadjiminis DJ, Sgourakis G, Al Mufti R, Karaliotas C. Modified Benelli approach for superior segmentectomy: a feasible oncoplastic approach. *Plast Reconstr Surg*. 2010;126:195e-7e.
11. Craft RO, Colakoglu S, Curtis MS, Yueh JH, Lee BS, Tobias AM, et al. Patient satisfaction in unilateral and bilateral breast reconstruction [outcomes article]. *Plast Reconstr Surg*. 2011;127:1417-24.
12. Ferguson DJ. Aesthetic and Reconstructive Breast Surgery. *JAMA: The Journal of the American Medical Association* 1983;250:3342-3.
13. Kaur N, Petit JY, Rietjens M, Maffini F, Luini A, Gatti G, et al. Comparative study of surgical margins in oncoplastic surgery and quadrantectomy in breast cancer. *Ann Surg Oncol*. 2005;12:539-45.
14. Berry MG, Fitoussi AD, Curnier A, Couturaud B, Salmon RJ. Oncoplastic breast surgery: a review and systematic approach. *J Plast Reconstr Aesthet Surg*. 2009;63:1233-43.
15. Grisotti A, Calabrese C. Conservative treatment of breast cancer: reconstructive issues. In: Spear SL, editor. *Surgery of the Breast: Principles and Art*. Philadelphia: Lippincott, Williams & Wilkins; 2006. p.147-78.
16. Spear SL, Pelletiere CV, Wolfe AJ, Tsangaris TN, Pennanen MF. Experience with reduction mammoplasty combined with breast conservation therapy in the treatment of breast cancer. *Plast Reconstr Surg*. 2003;111:1102-9.
17. Hester TR, Jr., Cukic J. Central breast pedicle and "free-hand" technique for alteration of volume and skin envelope of the breast. *Clin Plast Surg*. 1988;15:613-25.
18. Luini A, Gatti G, Galimberti V, Zurrida S, Intra M, Gentilini O, et al. Conservative treatment of breast cancer: its evolution. *Breast Cancer Res Treat*. 2005;94:195-8.
19. Sacchini V, Luini A, Tana S, Lozza L, Galimberti V, Merson M, et al. Quantitative and qualitative cosmetic evaluation after conservative treatment for breast cancer. *Eur J Cancer*. 1991;27:1395-400.
20. Cardoso MJ, Cardoso J, Santos AC, Vrieling C, Christie D, Liljegren G, et al. Factors determining esthetic outcome after breast cancer conservative treatment. *Breast J*. 2007;13:140-6.