CASE REPORT
https://doi.org/10.29289/2594539420260010

Malignant phyllodes tumor in a young female patient: a case report

Fernanda Beatriz de Albuquerque Feijó[1], Brenda Thomas[1], Debora Weiss[1]*, Camila Vitola Pasetto[1], Maria Helena Louveira[1], Vinicius Milani Budel[1], Lucas Roskamp Budel[1]

ABSTRACT

Phyllodes tumors of the breast are rare fibroepithelial neoplasms, accounting for less than 1% of breast neoplasms. The malignant subtype, accounting for 10% to 15% of cases, exhibits aggressive behavior, with a high risk of local recurrence and metastasis, primarily to the lungs and bones. This case report describes the clinical course and therapeutic challenges of a young female patient with a malignant phyllodes tumor in the left breast. The patient was a 23-year-old woman who presented with a rapidly growing tumor over less than six months, with extensive ulceration and destruction of the areola-nipple complex. Histopathological examination revealed a moderately differentiated spindle cell neoplasm with high stromal cellularity and a high mitotic index. The patient initially underwent isolated tumor resection, but experienced early recurrence, requiring a mastectomy with reconstruction using a latissimus dorsi flap. Following a new local recurrence, she underwent surgical intervention and adjuvant radiotherapy. With disease progression and the emergence of new lesions, she was referred for palliative treatment with chemotherapy. Clinical data were obtained from medical records, including the history, physical examination, imaging reports, operative descriptions, and histopathological analyses. The patient consented to the use of the information for scientific purposes by signing the informed consent form. The management of malignant phyllodes tumor of the breast represents a clinical challenge due to its low incidence and unpredictable biological behavior. Diagnostic and therapeutic approaches must be individualized and conducted by a multidisciplinary team, aiming to optimize oncological outcomes and provide the best possible care, even in the face of complex clinical situations.

KEYWORDS: breast neoplasm; phyllodes tumor; mastectomy; adjuvant radiotherapy; palliative care.

INTRODUCTION

The phyllodes tumor is a rare fibroepithelial neoplasm, accounting for 0.3% to 0.9% of breast neoplasms[1]. Histologically, it is classified as benign, borderline, or malignant, based on stromal cellularity, mitotic index, margins, and degree of atypia[1–3]. Malignant subtypes account for approximately 10% to 15% of cases[3–5] and originate in the breast stroma, differing from carcinomas, which develop in the glandular epithelium[4].

Clinically, they present as palpable, painless, mobile, and firm breast nodules[3], with rapid growth — a characteristic that aids in differentiation from fibroadenomas, especially when they reach large sizes[3,4]. Lesions larger than 10 cm are termed giant phyllodes tumors[5].

The initial diagnosis is made by imaging studies and confirmed by histopathology[1,3,4]. On mammography, they appear as oval or rounded masses, circumscribed and with iso- or hyperdense densities, resembling fibroadenomas. On ultrasound, they typically show lobulations, cystic areas, and marked posterior acoustic shadowing, suggesting malignancy. Magnetic resonance imaging may reveal lesions that are isointense on T1 and heterogeneously hyperintense on T2, with cystic findings more common in malignant subtypes[1,3].

The objective of this study was to report the clinical case of a patient diagnosed with a malignant phyllodes tumor, emphasizing the diagnostic challenges and the rarity of this condition.

[1]Universidade Federal do Paraná, Hospital de Clínicas – Curitiba (PR), Brazil.
***Corresponding author:** debora.weiss@outlook.com
Editor: Jordana de Faria Bessa https://orcid.org/0000-0002-8056-6295
Received on: 03/20/2026. **Accepted on:** 04/17/2026. **Published on:** 07/30/2026.
How to cite: Budel LR, Thomas B, Pasetto CV, Weiss D, Feijó FBA, Louveira MH, et al. Malignant phyllodes tumor in a young female patient: a case report. Mastology. 2026;36:e20260010. https://doi.org/10.29289/2594539420260010

CASE REPORT

All information presented in this report, as well as its images, were obtained after the patient signed the informed consent form, in accordance with the guidelines of the Code of Medical Ethics of the Brazil's Federal Council of Medicine (2009) and observing the ethical principles for medical research involving human subjects compiled in the Declaration of Helsinki (1964) and amended by the 52nd General Assembly of the World Medical Association in Edinburgh (2000). This report was approved by the Research Ethics Committee of the Federal University of Paraná, under opinion no. 7.793.561 and CAAE 91164425.5.0000.0096.

A 23-year-old female patient, previously healthy, reported a palpable 2-cm mass, classified as BI-RADS 3 on imaging studies performed in January 2024.

In August of the same year, she was referred to the emergency department of a tertiary care hospital due to progressive enlargement of the left breast associated with hyperemia and induration. Given the clinical presentation, she was admitted with a provisional diagnosis of mastitis, and antibiotic therapy with oxacillin was initiated. During the in, an ultrasound examination revealed a solid, heterogeneous lesion with cystic areas within it, irregular and indistinct contours, and a posterior acoustic shadow, occupying virtually the entire left breast, with approximate dimensions of 16.7×6.52 cm. The ultrasound characteristics were suggestive of a phyllodes tumor (BI-RADS 4). It was decided to perform a core biopsy of the solid portion of the lesion, in addition to drainage of the anechoic cavity, yielding 62 mL of thick, viscous, dark lemon-yellow fluid. Pathological examination revealed a moderately differentiated, extensively necrotic spindle cell neoplasm, and immunohistochemistry showed the following results: BCL2 antibody, clone 124 negative; CD34 antibody, clone Qbend10, multifocally positive; desmin antibody, clone D33, negative; MDM2 antibody, clone IF2, positive; vimentin antibody, clone V9, positive, diffuse; and pan-cytokeratin antibody, clone AE1/AE3, negative. Positivity for CD34 and vimentin, even with negativity for Bcl-2 and the absence of epithelial cells in the sample, does not rule out the possibility of a phyllodes tumor, and positivity for MDM-2 does not rule out an adipocytic neoplasm (liposarcoma), even in the absence of an adipocytic component in the sample. Complete negativity for pan-cytokeratin and desmin makes the diagnosis of metaplastic carcinoma and smooth muscle neoplasms, respectively, unlikely.

On August 26, 2024, the patient underwent left breast lumpectomy by the breast surgery team. Histopathological and immunohistochemical examination confirmed the diagnosis of malignant phyllodes tumor, showing involvement of the lateral surgical margin. The specimen, measuring 15.5×15,0×9.5 cm, showed diffusely distributed high stromal cellularity, associated with marked stromal atypia. A mitotic index greater than 10 mitoses per 5 mm^2 was also observed. The histological pattern of the tumor interface revealed infiltrative borders, with multifocal involvement of the surgical margins. In this sample, immunohistochemistry showed positivity for Bcl-2 (clone 124) and P53, with negativity for CD117 and CD34 (clone Qbend10).

The patient developed rapid local recurrence, necessitating extension of the surgical procedure. On October 14, 2024, a modified radical hygienic mastectomy of the left breast was performed with immediate reconstruction using a latissimus dorsi muscle flap (Figure 1). Despite preservation of the pectoral muscle, a 1.5×1,0×0.5 cm portion was excised for biopsy; histopathological examination revealed only fibroconnective tissue and skeletal striated muscle, free of neoplasia.

The mastectomy specimen measured 18×22×11 cm and weighed 1,922 g, presenting a breast surface with a pitted appearance. The tumor lesion, oval in shape, measured 20×16×9 cm, with well-defined borders. It was located 3 cm from the cranial margin, 0.1 cm from the caudal margin, 3 cm from the medial margin, 0.1 cm from the lateral margin, and 0.1 cm from the deep margin, indicating involvement of the lateral and caudal margins. The skin and nipple were free of neoplasia.

In November 2024, a new local recurrence was observed, presenting as two nodules in the area of the surgical scar (Figure 2). The patient underwent resection of the lesions on December 2, 2024; the pathological examination confirmed a phyllodes tumor,

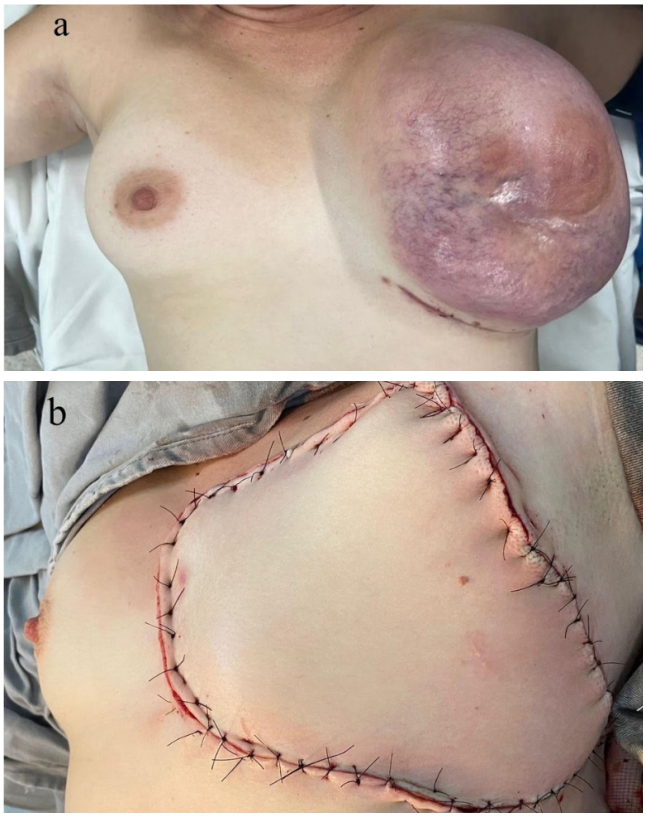

Figure 1. (a) Preoperative view before palliative mastectomy. (b) Immediate postoperative view after reconstruction with a latissimus dorsi flap.

with lesions measuring 10×6×4.5 cm and 9.5×4.8×4.5 cm, maintaining the characteristics of high and diffuse stromal cellularity, with atypia present in both lesions, and one of the lesions had all margins compromised by the neoplasm. As adjuvant treatment, she underwent radiation therapy between December 10, 2024, and January 22, 2025.

Despite the therapeutic measures implemented, a new local recurrence was identified in February 2025. A chest computed tomography scan performed during the same period revealed pulmonary metastases, with no possibility of surgical resection (Figure 3).

Due to the unresectability of the lesions, palliative chemotherapy with doxorubicin 25 mg.m^2 was initiated in March 2025, aiming for symptomatic control of the disease. Starting in May 2025, ifosfamide 1800 mg/m^2 was added to increase the response rate. In July of the same year, the maximum dose of doxorubicin (75 mg.m^2) was reached, and it was decided to use a regimen consisting solely of ifosfamide until September. In November, treatment with gemcitabine and docetaxel was initiated.

The patient required multiple hospitalizations for pain management. In November 2025, tests revealed a pathological fracture of the sternum associated with tumor infiltration, as well as left axillary lymphadenopathy and disease extension to the anterior mediastinum (Figure 4). As of December 2025, the patient remained under follow-up by the oncology, breast cancer, and palliative care teams, already meeting end-of-life criteria.

Figure 2. Preoperative marking of the local recurrence.

Figure 3. Chest computed tomography demonstrating pulmonary metastases.

DISCUSSION

Malignant phyllodes tumor is a rare neoplasm, accounting for a small fraction of breast tumors[3–5]. Its biphasic nature, composed of stroma and epithelium, confers unique characteristics that challenge the diagnostic and therapeutic approach[1–3,5,6].

Although phyllodes tumors are more common in middle-aged patients[3,4], around the age of 45[3], they can affect any age group, though they are uncommon in young and elderly women[4]. The present case highlights the occurrence in a young patient,

Figure 4. Chest computed tomography demonstrating local recurrence.

which demonstrates the complexity of the clinical management of this type of tumor, especially given its tendency to recur after aggressive surgical interventions.

Management of the case involves a multidisciplinary team from the time of diagnosis, with the radiologist's analysis of the mammogram and breast ultrasound being essential for raising suspicion, as well as the pathologist's confirmation of the correct diagnosis[2,5,6].

Certain histological markers are associated with a higher risk of recurrence and metastasis, such as a high mitotic index, marked stromal atypia, and an infiltrative growth pattern[3,4,6]. Tumors larger than 5 cm also have a poorer prognosis[3]. These markers are also important for classifying the tumor as benign, borderline, or malignant[3,4,6].

Regarding therapy, the treatment of choice is wide surgical excision[1,2,5], with margins of at least 1 cm and without the need for axillary dissection[3–5]. The presence of compromised margins, especially in malignant tumors, is associated with a higher risk of local or distant recurrence[2,3,7]. When adequate margins cannot be guaranteed, mastectomy should be considered[3,5]. Adjuvant radiotherapy may reduce the local recurrence rate[2–4], especially after breast-conserving surgery[2,3], although it does not affect overall survival. Adjuvant chemotherapy, however, remains controversial and is considered only in high-risk cases — such as tumors larger than 5 cm or with compromised margins where a new surgical approach is not possible[3,4].

In the reported case, the interval between diagnosis and the first surgery was less than 15 days, although the tumor presented with risk markers. Studies indicate that the median time to local recurrence of malignant phyllodes tumors of the breast ranges from 17 to 26 months after surgical treatment, with most recurrences occurring within the first two years[8]. The literature also reports that the five-year local recurrence rate ranges from 26% to 32%[8–10].

The patient initially presented with a malignant phyllodes tumor that allowed for conservative treatment; however, within less than three months, it required a radical surgical approach, resulting in a mastectomy, followed by a second surgical procedure due to a recurrence at the scar site, just 49 days after the mastectomy. Despite the complete removal of the primary tumor, the subsequent local recurrence after surgery highlights the biological aggressiveness of these tumors. Studies demonstrate that, even with adequate surgical margins, the recurrence rate for malignant phyllodes tumors can be high, ranging from 10% to 30%, depending on the histological grade and size of the initial tumor[3–5]. This highlights the importance of rigorous and continuous follow-up after surgery[4].

The patient underwent adjuvant chemotherapy and radiotherapy, strategies that have been used controversially in the treatment of phyllodes tumors[3,5,6], given the lack of robust evidence supporting their efficacy. The literature suggests that chemotherapy may not be as effective in phyllodes tumors, since these tumors may have a limited response to conventional chemotherapeutic agents[3].

The incidence of metastasis in malignant phyllodes tumors ranges from 6% to 25% of cases. Lymph node spread is uncommon, and metastases, when they occur, primarily affect the lungs and bones[3,6], as in the case described. These lesions typically have a poor response to chemotherapy and are associated with a poor prognosis[3]. The treatment of these metastatic neoplasms remains a challenge, as there is no established therapeutic consensus. The most frequently employed strategies include systemic chemotherapy based on anthracyclines and ifosfamide. After confirmation of metastatic disease, management takes on a predominantly palliative character[11,12].

Palliative chemotherapy with anthracyclines plays a limited role in the management of malignant phyllodes tumor of the breast following surgical treatment, and is indicated primarily in cases of metastatic or unresectable disease. The literature demonstrates that, following surgery, local recurrence and distant metastasis are common, and the prognosis in these scenarios is poor. The use of doxorubicin, alone or in combination with other agents such as ifosfamide, may provide modest palliative benefit, with a slight increase in survival compared to monotherapy or no chemotherapy, but without a significant impact on long-term overall survival[11,13–15].

Radiotherapy, although it may be beneficial in some cases to reduce the risk of local recurrence, does not have a well-defined role for all patients, especially those with low-grade tumors[3–5]. The most recommended regimen, according to the literature, is adjuvant radiotherapy with a total dose of 50 to 60 Gy in 25 to 30 fractions, directed at the tumor bed and margins, especially in cases of surgical margins <1 cm, positive margins, large tumors, or when further resection is not possible[16–20].

The patient's progression to a palliative condition, even after surgical interventions and adjuvant treatments, raises critical questions about management strategies for malignant phyllodes tumors. Recurrence in the context of aggressive treatment suggests that the intrinsic biology of the tumor may be a determining factor in treatment response.

CONCLUSION

Malignant phyllodes tumor of the breast is a rare neoplasm with unpredictable behavior and challenging management; its diagnosis is established by histopathology, and its treatment is based on surgical resection with adequate margins.

This case highlights the tumor's more aggressive presentation in a young patient, with successive early recurrences despite multiple surgical approaches and attempts at adjuvant therapies. Of particular note are the initial diagnostic difficulty and the impact of unsatisfactory locoregional control on the unfavorable

course, with rapid progression to advanced disease and the need for palliative care.

The report reinforces the importance of an appropriate surgical approach from the outset, rigorous follow-up, and high clinical suspicion in rapidly growing lesions, in addition to highlighting the limitations of adjuvant therapies and the need for better definition of their role in the management of these tumors.

ACKNOWLEDGEMENT

The authors express their sincere gratitude to the patient for providing informed consent for the publication of her clinical case for scientific and educational purposes. Her willingness to share her experience has contributed to the advancement of medical knowledge and to improving the understanding and management of similar clinical cases.

AUTHORS' CONTRIBUTIONS

LRB: Conceptualization, Investigation, Supervision, Writing – review & editing. BT: Conceptualization, Data curation, Investigation, Writing – original draft. CVP: Conceptualization, Investigation, Supervision, Writing – review & editing. DW: Conceptualization, Data curation, Investigation, Writing – original draft. FBAF: Conceptualization, Data curation, Investigation, Writing – original draft. MHL: Data curation, Investigation, Writing – review & editing. VMB: Supervision, Project administration, Writing – review & editing.

Funding: none.

Conflict of interests: nothing to declare.

Artificial Inteligence usage: none.

Data availability statement: The data supporting the results of this study are available upon request to the corresponding author, respecting patient confidentiality guidelines.

REFERENCES

1. Papas Y, Asmar AE, Ghandour F, Hajj I. Malignant phyllodes tumors of the breast: a comprehensive literature review. Breast J. 2020;26(2):240-4. https://doi.org/10.1111/tbj.13523
2. Basto R, Pereira TC, Rei L, Salgueiro FR, Magalhães J, Sousa MJ, et al. Giant metastatic breast phyllodes tumour with an elusive diagnosis: a case report and literature review. Eur J Case Rep Intern Med. 2021;8(8):e002763. https://doi.org/10.12890/2021_002763
3. Fede ÂBS, Souza RP, Doi M, De Brot M, Osorio CABT, Gondim GRM, et al. Malignant phyllodes tumor of the breast: a practice review. Clin Pract. 2021;11(2):205-15. https://doi.org/10.3390/clinpract11020030
4. Yasmin MC, Calvano Filho CMC. Tumor filoides maligno gigante: relato de caso e revisão da literatura. Rev Contemp. 2025;5(2):e7474. https://doi.org/10.56083/RCV5N2-063
5. Abdelwahab KM, Elsaeed S, Hamdy O, Saleh MM, Hosam A. Nipple-sparing mastectomy and immediate breast reconstruction by prepectoral implant for the management of giant phyllodes tumors: a case series. Breast Dis. 2024;43(1):231-6. https://doi.org/10.3233/bd-240011
6. Tan BY, Acs G, Apple SK, Badve S, Bleiweiss IJ, Brogi E, et al. Phyllodes tumours of the breast: a consensus review. Histopathology. 2016;68(1):5-21. https://doi.org/10.1111/his.12876
7. Lu Y, Chen Y, Zhu L, Cartwright P, Song E, Jacobs L, et al. Local recurrence of benign, borderline, and malignant phyllodes tumors of the breast: a systematic review and meta-analysis. Ann Surg Oncol. 2019;26(5):1263-75. https://doi.org/10.1245/s10434-018-07134-5
8. Xiao M, Zhu Q, Jiang Y, Li J, Wang H, Zhang J, et al. Local recurrent phyllodes tumors of the breast: clinical and sonographic features. J Ultrasound Med. 2015 Sep;34(9):1631-8. https://doi.org/10.7863/ultra.15.14.11012
9. Valenza C, De Pas TM, Gaeta A, Castellano G, Santoro C, Corona A, et al. Primary malignant phyllodes tumors of the breast: A retrospective analysis from a referral center. Eur J Cancer. 2024;196:113423. https://doi.org/10.1016/j.ejca.2023.113423
10. Han Y, Yu H, Li C, Jiang W, Shan H. Exploring the clinical and histopathological characteristics on breast phyllodes tumors predictors and prognosis in a real world. Front Oncol. 2025;15:1550429. https://doi.org/10.3389/fonc.2025.1550429
11. Moon SH, Jung JH, Lee J, Kim WW, Park HY, Lee JW, et al. Complete remission of giant malignant phyllodes tumor with lung metastasis: a case report. Medicine (Baltimore). 2019;98(22):e15762. https://doi.org/10.1097/md.0000000000015762
12. Han M, Zhang Y, Lei R, Lai Z, Zhuang Z, Zhang Y, et al. Prognostic factors and treatment insights for metastatic malignant phyllode tumors. Breast. 2025;81:104455. https://doi.org/10.1016/j.breast.2025.104455
13. Mituś JW, Blecharz P, Walasek T, Reinfuss M, Jakubowicz J, Kulpa J. Treatment of patients with distant metastases from phyllodes tumor of the breast. World J Surg. 2016;40(2):323-8. https://doi.org/10.1007/s00268-015-3262-7
14. Goodwin B, Oyinlola AF, Palhang M, Lehman D, Platoff R, Atabek U, et al. Metastatic and malignant phyllodes tumors of the breast: an update for current management. Am Surg. 2023;89(12):6190-6. https://doi.org/10.1177/00031348231198114

15. Balachandran NR, Abdullah N, Ismail MI, Wong YP, Azmi MI. Recurrent and transformation of borderline to malignant phyllodes tumour with osteoid differentiation: a case report and literature review. Front Oncol. 2024;14:1377074. https://doi.org/10.3389/fonc.2024.1377074

16. Boutrus RR, Khair S, Abdelazim Y, Nasr S, Ibraheem MH, Farahat A, et al. Phyllodes tumors of the breast: adjuvant radiation therapy revisited. Breast. 2021;58:1-5. https://doi.org/10.1016/j.breast.2021.03.013

17. Chao X, Chen K, Zeng J, Bi Z, Guo M, Chen Y, et al. Adjuvant radiotherapy and chemotherapy for patients with breast phyllodes tumors: a systematic review and meta-analysis. BMC Cancer. 2019;19(1):372. https://doi.org/10.1186/s12885-019-5585-5

18. Mitus JW, Blecharz P, Jakubowicz J, Reinfuss M, Walasek T, Wysocki WM. Phyllodes tumors of the breast: the treatment results for 340 patients from a single cancer centre. Breast. 2019;43:85-90. https://doi.org/10.1016/j.breast.2018.11.009

19. Wong RX, Koh YS, Wong FY, Kusumawidjaja G, Ng WL, Yeo RM, et al. The impact of radiotherapy and histological risk factors on outcomes in malignant phyllodes tumors. Clin Breast Cancer. 2020;20(6):e695-e700. https://doi.org/10.1016/j.clbc.2020.05.004

20. Ran Y, Li F, Qie S. A case report on the postoperative management of phyllodes tumor of the breast and literature review. Medicine (Baltimore). 2025;104(31):e43668. https://doi.org/10.1097/MD.0000000000043668

This is an open access article distributed under the terms of the Creative Commons license.