CASE REPORT
https://doi.org/10.29289/259453942026005

Radiation-induced breast angiosarcoma associated with germline BRCA1 mutation: a case report

Tiago Aléssio Rovaris[1]*, Maria Fernanda Souza De Luca[2], Bruna Aléssio Rovaris[3], Angel Gabriela Linden Borges da Silva[1]

ABSTRACT

Radiation-induced breast angiosarcoma (RIAS) is a rare, aggressive vascular neoplasm associated with prior radiotherapy, usually diagnosed at a late stage and with poor prognosis. This is the case of a 65-year-old female patient with a history of multiple cancers and a germline mutation in BRCA1, who developed RIAS. At age 57, she was diagnosed with triple-negative right breast carcinoma and underwent neoadjuvant chemotherapy, breast-conserving surgery, and adjuvant radiotherapy. With a positive BRCA1 panel, at age 61, the patient underwent a risk-reducing bilateral mastectomy. Approximately four months after surgery, rapidly progressing purplish lesions appeared on the right hemithorax, adjacent to the surgical scar. The biopsy, initially performed to investigate cancer recurrence, confirmed the diagnosis of breast angiosarcoma associated with previous radiotherapy (c-MYC positive). The staging computed tomography scan revealed extensive dermal infiltration, rendering surgical treatment unfeasible, thus leading to the recommendation for palliative management with radiotherapy and adjuvant chemotherapy with docetaxel and gemcitabine.

KEYWORDS: hemangiosarcoma; breast neoplasms; radiotherapy; mastectomy; adjuvant chemotherapy.

INTRODUCTION

Breast angiosarcomas can be of primary or secondary origin, mainly related to radiation or chronic lymphedema, the latter associated with Stewart-Treves syndrome following treatment for breast cancer[1,2,3].

Radiation-induced breast angiosarcoma (RIAS) is a rare and aggressive disease composed of neoplastic endothelial cells that affects approximately 0.04% to 0.10% of patients undergoing radiotherapy (RT) after conservative treatment for breast cancer, and rarely after mastectomy. With the increased use of this surgery followed by RT, there has been a rise in the number of reports on the disease in the literature[2,4,5].

This tumor is defined by the development of cancer cells within the area previously treated with RT, a latency period of several years following radiation — with most cases occurring around six years later — and the presence of histological patterns that differ from those observed in the primary tumor[1].

The age at diagnosis is around 70 years, with a high rate of local recurrence and a propensity for metastatic spread, especially to the lungs and liver, and an extremely low overall survival rate of 20% at five years[3,4].

The objective of this study was to report a case of RIAS treated with RT and adjuvant chemotherapy (CT), as well as to highlight the differential diagnosis of late-onset skin lesions following conservative treatment of breast cancer, considering the severity of the disease and the need for early diagnosis to improve outcomes.

CASE REPORT

The patient T.M.F. is a 65-year-old woman with a complex oncological history who developed RIAS following treatment for breast cancer, a rare condition of significant clinical interest.

She was initially diagnosed with ovarian cancer at age 39, with recurrence at age 42. Subsequently, at age 47, she presented with retroperitoneal liposarcoma, with a new recurrence at age 51. At age 57, she was diagnosed with triple-negative right breast cancer and underwent neoadjuvant CT followed by breast-conserving surgery and adjuvant RT.

[1]Universidade do Extremo Sul Catarinense – Criciúma (SC), Brazil.
[2]Sociedade Literária e Caritativa Santo Agostinho, Hospital São José – Criciúma (SC), Brazil.
[3]Faculdade Ceres – São José do Rio Preto (SP), Brazil.
***Corresponding author:** tiagoarovaris@gmail.com
Editor: Marcelo Antonini
Received on: 02/15/2026. **Accepted on:** 03/16/2026. **Published on:** 05/15/2026.
How to cite: Rovaris TA, De Luca MFS, Rovaris BA, da Silva AGLB. Radiation-induced breast angiosarcoma associated with germline BRCA1 mutation: a case report. Mastology. 2026;36:e2026005. https://doi.org/10.29289/259453942026005

At age 61, she underwent genetic testing, which identified a pathogenic mutation in BRCA1, leading to the recommendation of bilateral risk-reducing mastectomy. In the preoperative period, she presented with cutaneous edema in the previously irradiated breast, classified as BI-RADS 4 on imaging studies, and a skin biopsy was indicated, the result of which was negative for neoplasia (Figure 1). The patient underwent bilateral simple mastectomy, with no neoplasia identified.

Approximately four months after the procedure, the patient developed rapidly progressing violaceous skin lesions on the right hemithorax, near the surgical scar (Figure 2). Given the diagnostic hypothesis of breast cancer recurrence, a biopsy of the lesions was performed, with histopathology consistent with poorly differentiated carcinoma infiltrating the dermis (Supplementary Figure S1). Immunohistochemical analysis showed positivity for CD34, CD31, and c-MYC (Supplementary Figure S2), as well as a Ki-67 index of 90%, which are consistent with RIAS.

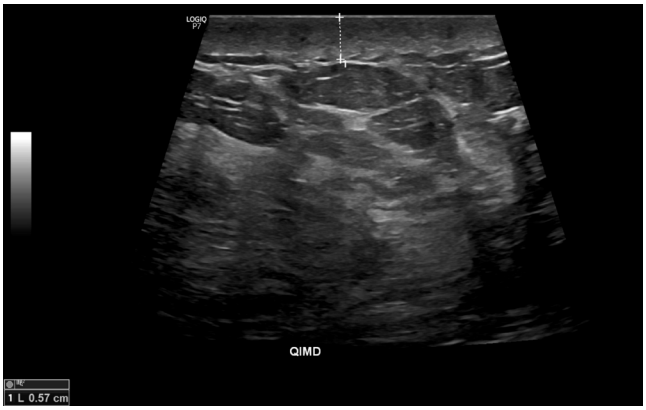

Figure 1. Ultrasound showing suspicious late-onset skin thickening in the inferomedial quadrant of the breast.

Figure 2. Rapidly progressing violaceous skin lesions in the right hemithorax, near the surgical scar from a recent mastectomy.

Staging computed tomography revealed extensive infiltration, precluding surgical treatment (Figure 3). Therefore, palliative treatment with RT and adjuvant CT based on docetaxel and gemcitabine was chosen.

During follow-up, the patient developed pleural ulceration and pleural effusion. Analysis of the pleural fluid revealed that it was secondary to the effects of RT, with no evidence of neoplastic spread to the lung or pleura. Currently, the patient is under the care of plastic surgery and thoracic surgery teams in an attempt to close the skin ulcer.

DISCUSSION

With the increased use of breast-conserving surgery followed by RT and the expanded indications for RT after mastectomy for the treatment of early-stage breast cancer, it has been observed that, although this therapy is used to minimize local recurrences and improve overall survival, there is a possibility of developing late effects, such as secondary neoplasms of epithelial (carcinomas) and mesenchymal (sarcomas) origin. Although the risk is relatively low and angiosarcomas are less common after radiation, they are the most common type of sarcoma following breast irradiation[6,7]. In a large Dutch population-based study, RIAS was a rare complication (1 in 1,000) that occurred exclusively in irradiated patients, with a median latency of eight years and a poor prognosis[8]. In turn, another large American study with 19,289 cases (2001–2020) demonstrated that the incidence of angiosarcoma is increasing, mainly due to the rise in secondary cases among

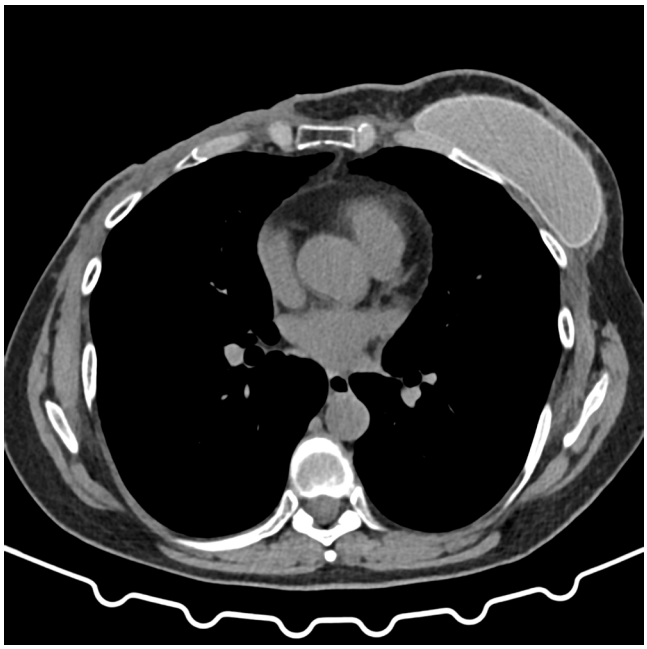

Figure 3. Computed tomography scan showing skin thickening and irregularity over the surgical scar.

women with a history of breast cancer, highlighting the need for greater surveillance in at-risk groups[9]. The development of RIAS is directly related to the radiation dose and the time elapsed since treatment (latency)[7]. RT for breast cancer is generally administered at a maximum dose of 50 Gy to the operated area and, in some cases, with an additional "boost" of 10 to 20 Gy[10].

Regarding the pathogenesis of RIAS, it is known that photons released during RT can cause direct DNA damage, especially through double-strand breaks. In addition, radiation promotes the generation of free radicals, which intensify oxidative stress and produce additional lesions in the genetic material, such as single-strand breaks and the formation of base sites. Together, these processes result in genomic instability, creating a scenario conducive to the development of neoplasms[4].

For decades, the gold standard for adjuvant RT following breast surgery has been conventional regimens, lasting approximately five weeks, with well-established oncological and cosmetic outcomes. In recent years, studies have shown that moderate hypofractionated treatment, which uses higher daily radiation doses over fewer sessions and, consequently, a lower total accumulated dose, has yielded similar results regarding oncological and aesthetic outcomes, as well as quality of life, when compared to conventional fractionation. More recently, it has been observed that even shorter regimens, such as those in the FAST-Forward study, were not inferior to the more traditional regimen and had a similar toxicity profile. Although contemporary regimens have a lower total accumulated dose, suggesting reduced tissue risk, it is still too early for a definitive assessment regarding the risk of secondary neoplasms such as RIAS[11,12,13].

Regarding genetic alterations, some have already been described in the literature, such as the inactivation of the TP53 tumor suppressor gene and the amplification of the 8q24.21 region, where the c-MYC proto-oncogene is located—a highly specific marker for secondary angiosarcomas and important for differential diagnosis with primary tumors. Furthermore, in conjunction with c-MYC positivity, the overexpression of Fms-related tyrosine kinase 4 (FLT4) is associated with increased endothelial growth factors involved in lymphangiogenesis, which also contribute to gene amplification. Recent studies have demonstrated that high-level amplification of the MYC gene is a characteristic of secondary angiosarcomas, whether related to prior RT or chronic lymphedema. Thus, the presumptive diagnosis of RIAS is based on a clinical history of prior RT at the affected site[4,14]. Finally, there may also be an association between the BRCA1/BRCA2 tumor suppressor genes related to breast cancer and RIAS, considering that these genes may double the risk of angiosarcoma, although the exact relationship has not yet been established[3,4].

Thus, as mentioned earlier, the genesis of secondary angiosarcoma can be understood from three different perspectives: microenvironmental changes, as occurs in Stewart-Treves syndrome, radiation exposure, and germline genetic predisposition, with Li-Fraumeni syndrome being a prominent example. In the latter, mutations in TP53 compromise the function of the p53 protein in response to DNA damage, promoting genomic instability and increasing the risk of sarcomas, including in previously irradiated areas[15].

The clinical presentation of RIAS tends to be insidious, often characterized by painless hematomas that initially appear benign. Areas of violaceous discoloration, eczematous eruptions, hematoma-like edema, and diffuse breast enlargement may also occur, contributing to delays in diagnosis[1,4]. Diagnostic confirmation is obtained through skin puncture or incisional biopsy, whose histological findings reveal aberrant vascular channels lined by cells with hyperchromatic nuclei and pleomorphic features[1]. Immunohistochemistry plays a central role in diagnostic clarification, particularly with the expression of the aforementioned c-MYC and the endothelial markers CD31 — recognized as the most sensitive and specific indicator of neoplastic angiogenic proliferation — Factor VIII, Fli1, and CD34[1].

Mammography has low specificity for angiosarcoma, generally revealing masses or asymmetries that are not particularly characteristic and may produce false negatives due to glandular density, most often visualized as non-calcified, poorly defined nodules. In some cases, it may show fatty changes, thus potentially including hemangioma and angiolipoma as differential diagnoses. Ultrasonography is also nonspecific, showing hypoechoic, hyperechoic, or heterogeneous lesions with a gradual transition to adjacent tissue. Although contrast-enhanced ultrasound assesses tumor perfusion, specific patterns for angiosarcoma have not yet been described. Magnetic resonance imaging is the most sensitive method, revealing heterogeneous signal intensity and enhancement consistent with high vascularization and detecting lesions not visible on mammography. Together, these imaging modalities do not provide definitive diagnostic criteria, and confirmation depends on histopathological and immunohistochemical evaluation[2,5,16].

Angiosarcoma is considered a radiation-resistant neoplasm, with surgical resection as the first-line treatment; CT may be considered when there is a risk of distant metastasis. However, evidence from retrospective series suggests that radical RT may be a therapeutic alternative in selected situations, particularly in aggressive, locally advanced, and inoperable cases where surgical treatment is not an option. In addition, low-dose RT regimens, such as 10 Gy in hypofractionated fractions, have demonstrated significant reduction in tumor volume and symptomatic control, indicating possible radiosensitivity in specific subgroups of patients[17].

In fact, palliative CT also constitutes a relevant therapeutic alternative in situations where surgical resection is not feasible. Various CT regimens have been used for this purpose, including anthracyclines (doxorubicin and epirubicin), taxanes (docetaxel and paclitaxel), and gemcitabine, with heterogeneous results among reported cases[4].

The prognosis for breast angiosarcoma is notoriously poor, with 5-year survival rates ranging from 28% to 54%. Evidence indicates significantly higher mortality in RIAS compared to primary angiosarcoma, primarily due to older age, higher histological grade, and more advanced tumor stage at diagnosis. There are reports linking pregnancy or lactation to a more aggressive course of the disease[5,6].

CONCLUSIONS

RIAS is a rare and aggressive neoplasm with a late and insidious presentation, which develops primarily as a result of treatment for previous cancer of the breast. The diagnosis is made via excisional biopsy or skin biopsy, with immunohistochemistry to confirm the tumor's angiogenic origin. The first-line treatment for RIAS is surgery. However, in inoperable cases, such as that of the patient in this case report, RT and adjuvant CT may be used as palliative treatment.

ACKNOWLEDGEMENT

We thank the Mastology Department at Hospital São José for their support in managing the case. We also thank the patient for her collaboration and consent for publication, and Dr. Alessandra Beatris Aléssio Rovaris for her encouragement and assistance in formulating this case study.

ETHICAL CONSIDERATIONS

This study was approved by the Research Ethics Committee of Hospital São José (in the State of Santa Catarina), under CAAE No. 94464525.7.0000.5364, in accordance with Resolution No. 466/2012 of the National Health Council of Medicine and originally registered under the title "Radiation-induced breast angiosarcoma: case report". There are no conflicts of interest among the authors. The patient agreed to participate and signed an informed consent form.

AUTHORS' CONTRIBUTIONS

TAR: Conceptualization, Data curation, Formal Analysis, Investigation, Project administration, Visualization, Writing – original draft. MFSL: Conceptualization, Methodology, Supervision, Validation, Writing – review & editing. BAR: Data curation, Formal Analysis, Investigation,Project administration, Writing – original draft. AGLBS: Data curation, Formal Analysis, Investigation, Project administration, Writing – original draft.

Funding: none.

Conflict of interests: nothing to declare.

Artificial intelligence usage: The authors used artificial intelligence to assist with language editing and text organization. All content was reviewed and approved by the authors.

Data availability statement: The data supporting the results of this study are available upon request to the corresponding author, respecting patient confidentiality guidelines.

Supplementary material: https://drive.google.com/file/d/1jUJo_HFixIvX1B1cfF_NsYlWT8higdRO/view?usp=sharing

REFERENCES

1. Binotto ALC, Felitti S, Lopes de Paula LC, Silva MS, Dini VR. Angiossarcoma Radioinduzido Em Mama: Relato de Caso. JMRReview. 2025;4(00):e083. https://doi.org/10.37497/JMRReview.v4i00.83
2. Glazebrook KN, Magut MJ, Reynolds C. Angiosarcoma of the breast. AJR Am J Roentgenol. 2008;190(2):533–8. https://doi.org/10.2214/AJR.07.2909
3. Oliveira LAA, Pádua Filho AF, Melo MAM, Galvão ERCGN, Vieira MC, Ibiapina JO, et al. Angiossarcomas induzido por radiação: relato de caso. Einstein (São Paulo). 2020;18:eRC5439. https://doi.org/10.31744/einstein_journal/2020RC5439
4. Cozzi S, Ghersi SF, Tava F, Bardoscia L, Najafi M, Ruggieri MP, et al. Radiation-associated angiosarcoma of the breast: the state of the art of a rare and aggressive disease. J Pers Med. 2024;14(8):859. https://doi.org/10.3390/jpm14080859
5. An R, Men XJ, Ni XH, Wang WT, Wang CL. Angiosarcoma of the breast: a review. Heliyon. 2024;10(3):e24413. https://doi.org/10.1016/j.heliyon.2024.e24413
6. Mergancová J, Lierová A, Coufal O, Žatecký J, Melichar B, Zedníková I, et al. Radiation-associated angiosarcoma of the breast: An international multicenter analysis. Surg Oncol. 2022;41:101726. https://doi.org/10.1016/j.suronc.2022.101726
7. Silva Neto LA, Lira JBSO, Nóbrega LP, Pereira MGC. Efeito rebote a longo prazo em pacientes submetidas ao tratamento radioterápico do câncer de mama: revisão de literatura. Res Soc Dev. 2024;13(11):e150131147505. https://doi.org/10.33448/rsd-v13i11.47505

8. Rombouts AJM, Huising J, Hugen N, Siesling S, Poortmans PM, Nagtegaal ID, et al. Assessment of Radiotherapy-Associated Angiosarcoma After Breast Cancer Treatment in a Dutch Population-Based Study. JAMA Oncol. 2019;5(2):267–9. https://doi.org/10.1001/jamaoncol.2018.6643
9. Wagner MJ, Ravi V, Schaub SK, Kim EY, Sharib J, Mogal H, et al. Incidence and presenting characteristics of angiosarcoma in the US, 2001-2020. JAMA Netw Open. 2024;7(4):e246235. https://doi.org/10.1001/jamanetworkopen.2024.6235
10. Seinen JM, Styring E, Verstappen V, Steyern FVV, Rydholm A, Suurmeijer AJH, et al. Radiation-associated angiosarcoma after breast cancer: high recurrence rate and poor survival despite surgical treatment with R0 resection. Ann Surg Oncol. 2012;19(8):2700–6. https://doi.org/10.1245/s10434-012-2310-x
11. Fang M, Marta GN. Hypofractionated and hyper-hypofractionated radiation therapy in postoperative breast cancer treatment. Rev Assoc Med Bras. 2020;66(9):1301–6. https://doi.org/10.1590/1806-9282.66.9.1301
12. Fang M, Gico VC, Casimiro L, Takatsu B, Santos Neto E, Lopez RVM, et al. Phase II evaluation of ultra-hypofractionated postoperative radiation therapy for breast cancer: toxicity and efficacy in a single-center nonrandomized prospective study. JCO Glob Oncol. 2025;11:e2400277. https://doi.org/10.1200/GO-24-00277
13. Brunt AM, Haviland JS, Wheatley DA, Sydenham MA, Alhasso A, Bloomfield DJ, et al. Hypofractionated breast radiotherapy for 1 week versus 3 weeks (FAST-Forward): 5-year efficacy and late normal tissue effects results from a multicentre, non-inferiority, randomised, phase 3 trial. Lancet. 2020;395(10237):1613–26. https://doi.org/10.1016/s0140-6736(20)30932-6
14. Manner J, Radlwimmer B, Hohenberger P, Mössinger K, Küffer S, Sauer C, et al. MYC high-level gene amplification is a distinctive feature of angiosarcomas after irradiation or chronic lymphedema. Am J Pathol. 2010;176(1):34–9. https://doi.org/10.2353/ajpath.2010.090637
15. Kamihara J, Rana HQ, Garber JE. Germline TP53 mutations and the changing landscape of Li-Fraumeni syndrome. Hum Mutat. 2014;35(6):654–62. https://doi.org/10.1002/humu.22559
16. Freire F, Barra FR, Camelo REFA, Ribeiro ACO, Farage L, Andrade LF. Angiossarcoma primário de mama: desafio diagnóstico. Mastology. 2017;27(1):47–9.
17. Ikenohira T, Konishi K, Hirata M, Ohira K, Nakamura K. Radical radiation therapy for radiation-induced angiosarcoma with local control. Case Rep Oncol. 2021;14(3):1779–84. https://doi.org/10.1159/000519596

This is an open access article distributed under the terms of the Creative Commons license.