CASE REPORT
https://doi.org/10.29289/2594539420220039

Breast angiolipoma in young woman: case report

Nathalia Silva Queiroz[1]*, Vitor Silva[1], Marcelo Ballaben Carloni[1]

ABSTRACT

This case report describes a benign breast tumor, more specifically, an angiolipoma, in a 17-year-old female patient who presented with a nodule in the left breast, painful to palpation. The nodule is at an atypical breast site and has few records in the literature, which were considered in this description that aims at identifying the main histological, ultrasound, mammographic and immunohistochemical characteristics of breast angiolipoma; besides informing other professionals about the possible angiolipoma diagnosis when considering a benign breast tumor, despite its rare occurrence.

KEYWORDS: angiolipoma; breast; women.

INTRODUCTION

Angiolipoma is a benign variant of the lipoma, corresponding to indices that range from 5% to 17% of the benign lipomatous tumors. Composed of mature fat tissue and blood capillaries[1], it is usually presented as a painful mass that is mostly found in the trunk and in the forearm and can manifest itself as multiple nodules[2]. It can be preceded by an existing lipoma with posterior induction of vascular proliferation caused by repeated trauma at the site[3].

Breast angiolipoma, unlike the angiolipoma in other sites, is usually painless[4]. Besides, it is more commonly presented as a single tumor, shown in men as a bulge in the breast region, and in women, because of the fibroglandular breast tissue, as a palpable mass, with no bulges[2]. Most of the time, clinical investigation begins with the complaint of a palpable breast nodule or with the occasional finding of a nodular image in a routine mammography. Since there are no typical mammography characteristics for breast angiolipoma, additional examinations are required to rule out malignancy[4].

In this sense, the investigation continues with the complement of an ultrasound, in which the tumor can be visualized as an ovoid, homogeneous, echogenic and isodense mass[3]. The image on the ultrasound is compatible with benign characteristics, once the echogenicity associated with well-defined margins provides a certain negative predictive value for malignancy[4].

Even though the images mostly present aspects of benignity, it is not possible to distinguish the types of benign solid neoplasms, nor to rule out malignant conditions; therefore, it is ideal to perform a biopsy to conclude the diagnosis[5].

Biopsy shows the specific characteristics of a breast angiolipoma, which allow its identification. In the histopathological analysis, such aspects are shown by the presence of mature fat cells related to the proliferation of vessels and intravascular hyaline thrombi, and at the absence of necrosis, mitosis, atypia or cellular proliferation[3]. The dispersion of microthrombi in the capillaries is the main aspect of this tumor[4]. Also in the microscopic evaluation, angiolipomas can be classified as infiltrating or non-infiltrating, both without potential for malignancy.

In the breast, these edemas belong to the non-infiltrating category; therefore, as a therapeutic measure, a simple excision is sufficient, unlike those of the infiltrating type, found in other regions of the body, which requires the excision with safety margins to prevent recurrence[4].

The occurrence of this slow growth mesenchymal neoplasm is rare in sites such as the breast; therefore, in this situation, its report is essential to consider breast angiolipoma as one of the diagnostic possibilities of benign breast tumor.

CASE REPORT

A female,17-year-old patient, was referred with priority to the outpatient mastology clinic due to a breast ultrasound with BI-RADS4 report.

At the first appointment, the patient mentioned feeling a nodule at the parasternal region of the left breast for three months, with no phlogistic signs and painful only at palpation. Besides, she had no complaints associated with this region of the breast, such as mastalgia or altered sensitivity. As to previous history, the patient denied having previous pathologies, as well as surgeries or blood transfusions. She did not take contraceptive drugs nor other continuous use

[1]Centro Universitário Municipal de Franca – Franca (SP), Brazil.
***Corresponding author:** nanasqueiroz@gmail.com
Conflict of interests: nothing to declare. **Funding:** none.
Received on: 09/09/2022. **Accepted on:** 10/18/2022.

medicine. At physical examination, there was palpation of a regular and small movable nodule, of fiber elastic consistency, measuring 1.5 cm in an inferomedial quadrant to the left, parasternal. In the breast ultrasound brought in by the patient, the right breast was normal with the presence of a solid, hyperechogenic nodule, with an echogenic, heterogenous, oval hallo, with no Doppler flow, measuring 13x6x12.8 mm. Besides, a round lymph node with cortical hypertrophy was observed, measuring 10 mm, in the left axillary region. Its origin was questioned – reaction or atypical.

With medical guidance, to analyze the tissue origin through a biopsy, the patient was given two options: ultrasound-guided core biopsy or nodule excision with posterior anatomopathological analysis. The choice of the patient was for the excision of the parasternal nodule to the left. In the following appointment, the same characteristics observed in the previous physical examination were found, except for a 2.5 cm increase in the nodule. We emphasize that the clinical examinations identified free axilla.

Before surgery, some examinations were required, and the results were normal. Therefore, one month after the first appointment, the excision biopsy was performed, and the material was sent for anatomopathological evaluation. In the post-surgical analysis, the patient showed good general status, was asymptomatic, the scar had good aspect and she had no phlogistic signs. The anatomopathological report pointed to an encapsulated nodule constituted by fibroblast and lipomatous proliferation, with mild atypia, myxoid stroma and free surgical margins.

For a complementary evaluation, the material was sent for immunohistochemical analysis (IHA) (Table 1). The result showed that the nodule was a lesion formed by adipocytes associated with the proliferation of small caliber vessels, especially capillary ones, in a collagenized stroma with absence of atypia in endothelial cells and adipocytes.

Besides, there was the expression of CD34 in the blood vessels (Figure 1).

Vascular proliferation was prevalent in the fat tissue in most of the tumor. Hence, the angiolipoma was diagnosed (cellular variant). It is worth to mention that this is a benign neoplasm with excellent prognosis and low risk of local recurrence.

The patient was oriented about the nodule's benignity, as well as its rare occurrence in the breast.

This case report was submitted to and approved by the Research Ethics Committee of Fundação Santa Casa de Misericórdia de Franca, through Plataforma Brasil (Certificate of Presentation for Ethical Consideration — CAAE: 60193522.4.0000.5438). The study has no funding and the authors do not have conflicts of interest to declare.

DISCUSSION

Breast angiolipoma — clinical aspects

The breast is an atypical site for the angiolipoma, and there are few cases described in the literature. Its occurrence among men is even rarer.

The clinical presentation usually involves a complaint about a non-painful breast nodule, not associated with changes in the skin or papillary secretion, as well as to the absence of axillary adenopathy[4]. The case reported here coincides with such data, since the patient presented with pain only at palpation, without associated skin changes.

The case reports in the literature range much; from a woman with previous history of breast carcinoma, who presented with a non-sensitive firm and movable mass in the contralateral breast, to a male patient referring increased sensitivity on the left breast, in which a tumor was found only in the ultrasound. As to mammography changes, none was visualized, not even at the clinical examination[3,4].

Breast angiolipoma — changes in images

Breast nodules require detailed investigation in order to clarify the etiology and define is handling, which is possible through image examinations in order to characterize the aspect of the tumor[2].

Regarding the mammography aspect, the breast angiolipoma is visualized as an oval, isodense and circumscribed mass[5]. However, there are no pathognomonic radiological characteristics for these lipomatous tumors[2].

Table 1. Immunohistochemical analysis.

Antibodies	Clone	Result	Obs./Block
DDIT3	9C8	Negative	(2128/21)
SOX-10	BC34	Negative	(2128/21)
MDM2	SMP14	Negative	(2128/21)
CDK4, cyclin-dependent kinase 4, clone DCS-31	DCS-31	Negative	(2128/21)
S-100 Protein	Polyclonal	Focally positive	adipocytes (2128/21)
40, 48, 50 and 50.6 kDa cytokeratins	AE1/AE3	Negative	(2128/21)
Desmin (intermediate filamento, muscle cell)	D33	Negative	(2128/21)
CD34 – hematopoietic cell antigens and pericytes	QBEnd 10	Positive	blood vessels (2128/21)
Epithelial membrane antigen	E29	Negative	(2128/21)

DDIT3: DNA Damage Inducible Transcript 3; SOX-10: SRY-box transcription factor 10; MDM2: mouse double minute 2; CDK4: Cyclin-dependent kinase 4; PROTEINA S-100: S-100 BETA.

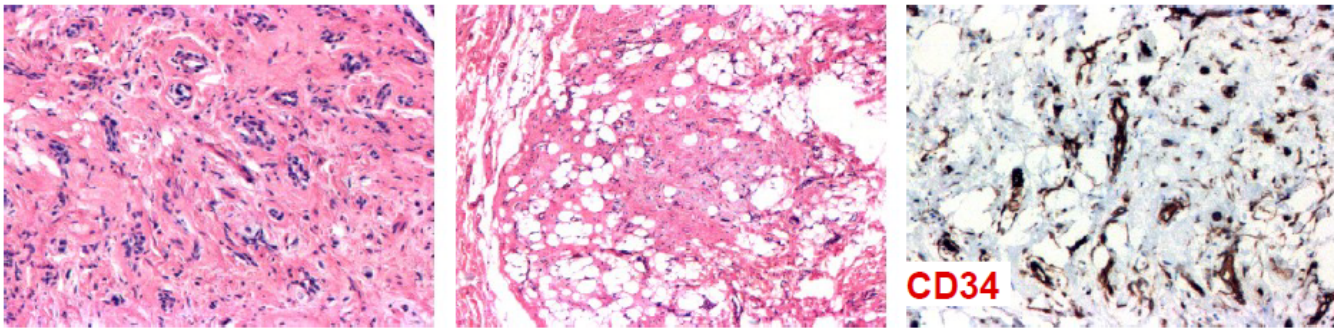

Figure 1. Positivity for CD34.

The ultrasound can be considered as complementary to mammography, once it better assesses the margins of the tumor and defines its echogenicity.

As to the echogenic aspect, the breast angiolipoma presents characteristics not so often found in other types of breast nodules. Usually, a homogeneously echogenic tumor is visualized[4]; therefore, the hypothesis of breast angiolipoma should be considered when an isoechoic or uniform hyperechoic, homogeneous nodule, with well-circumscribed margins, is found[1,5]. In this report, the ultrasound brought by the patient showed an oval, solid, hyperechogenic nodule with echogenic hallo; however, unlike the cases described in the literature, it was heterogeneous.

Breast angiolipoma — histopathological aspects

The imaging resources are insufficient for a definitive diagnosis of breast angiolipoma; therefore, a biopsy is indicated[5]. In the described case, the patient chose to undergo an excision of the breast nodule, which was then sent for anatomopathological evaluation.

The site of the angiolipoma in the breast carries a diagnostic challenge. Since this is an organ that is rich in fat tissue, the accuracy of the core biopsy can be questioned for associating the fat tissue to a wrongful sample of the region that is subjacent to the lesion, and not to the lesion itself[2].

The fine needle aspiration puncture (FNA) can also be performed. Usually ultrasound-guided, the cytologic evaluation reveals mature fat cells[3].

The histopathological analysis of the breast angiolipoma is marked by specificities, such as the visualization of hypertrophic adipocytes associated with capillary proliferation; however, the latter can cause from minor changes in the tumor structure to angiomatosis[2]. An angiolipoma composed of highly cellular and vascular tissue (about 90% of the lesion) is classified as cellular angiolipoma[3]. The opposite is true, once those with little development of the vascular component are classified as angiolipomas of low vascularity[2].

In this case report, the histopathological result showing fibroblastic and lipomatous proliferation with mild atypia was not sufficient to confirm the diagnosis of breast angiolipoma; therefore, it was necessary to perform a immunohistochemical analysis. So, though the latter, the diagnosis was concluded by the existence of adipocytes associated with vascular proliferation of small capillaries, which were prevalent on the fat tissue, which is characteristic of the cellular variant.

Besides, it is worth to mention that the presence of hyalin intravascular thrombi is a highly suggestive finding to identify breast angiolipoma[3]. One description in the literature mentioned, despite being rare, the presence of calcification in this type of tumor, suggesting that its formation was owed to the calcification of some of these intravascular thrombi[1].

Some pathological criteria used to identify the breast angiolipoma are described in the literature as having a gross tumor appearance, visualized after the excision, with or without capsule and microscopic features, such as mature lipocytes, corresponding to more than 50% of the tumor, as well as vascular proliferation[1]. However, nowadays it is known that the proportion of these two mesenchymal elements vary, so the level of vascular proliferation of the injury can range from less than 5% to more than 90%[3].

Macroscopically, after the removal of the edema, a yellowish encapsulated nodule was observed, which usually does not overcome 2 cm in diameter[4].

Breast angiolipoma — vascularization and relation with imaging examinations

The level of development of vascularization of angiolipomas, as approached before, can range, and such a characteristic seems to reverberate in the evaluation of mammography and ultrasound images. The low vascularity angiolipomas are bigger lesions, which usually present as palpable masses perceived by the patient. This type of lesion tends to be visualized in the ultrasound; however, it cannot be identified in the mammography[2].

Cellular angiolipomas, which are highly vascularized, are smaller and usually undetected at palpation. Unlike those with low vascularity, the characteristic of this type is its identification in mammography, however, without abnormalities in the ultrasound[2]. These are mostly found among older women during screening mammography, since they are usually not palpable[2]. Despite being the type found in the patient in question, it could be visualized in the ultrasound, as well as palpated at physical examination.

A study about mammography and ultrasound resources in the evaluation of breast angiolipoma confirmed the tendency

that masses composed of more than 50% of vascular component are visible at mammography, that is, vascularization gives the angiolipoma more density, thus allowing a better visualization of these masses through the x-ray when compared to the one with more fat, in which the fat component is prevalent[5].

Breast angiolipoma — diagnosis and treatment

As previously mentioned, despite the benignity indicated by the imaging examinations, the diagnosis can only be concluded after the histopathological analysis. Well established by the core biopsy, ensuring the benign aspects of the lesion, with no atypia or mitosis, it is optional to remove or maintain the lesion, once its potential for malignancy is minimum; therefore, it would not lead to future damage[2]. There is an exception for cellular angiolipomas, which can mimic signs of malignancy, and the core biopsy is not sufficient to rule it out; therefore, the excision of the mass is recommended[2].

To remove a non-infiltrating breast angiolipoma, the safety margins may not be necessary; as for the infiltrating type, they are indispensable in order to prevent the recurrence of this tumor[4].

Breast angiolipoma — differential diagnosis

The main differential diagnosis to be included for the identification of angiolipomas is the low-grade or well-differentiated angiosarcoma. This characteristic does not allow the angiosarcoma to have high mitotic index or atypia, which can be easily considered as the angiolipoma[2].

The angiosarcoma can primarily appear in patients aged between 20 and 40 years and among the elderly; secondarily, in people with history of radiotherapy or axillary lymph node dissection resulting from chronic lymphedema. Other findings, besides clinical history, is the extravasation of blood in the angiosarcomas, turning the skin purple, and its visualization in the ultrasound as a large tumor associated with heterogeneous echogenicity. Most cellular angiolipomas are not visible in the ultrasound.

Finally, tumors rarely exceed the size of 2 cm in diameter, whereas angiosarcomas are larger than that[2].

CONCLUSION

Breast angiolipoma is a rare diagnosis; therefore, this case report describes its occurrence in a young woman. In that sense, in order to better characterize, it, the objective was to list the main necessary aspects to investigate the diagnostic suspicion considering the benign breast tumor. Such aspects involved imaging examinations, however, due to the nonspecificity of the findings, it was necessary to perform an anatomopathological evaluation. The presence of fat tissue, associated with vascular proliferation, confirms the angiolipomatous etiology of the nodule.

As in the case description, it is observed that other examinations can be necessary to back up such a confirmation when the anatomopathological evaluation is not clear. It is worth to mention that the benignity of such finding, when not accompanied by atypia, ensures good prognosis, which allows to choose whether to remove it or not.

It is important to mention that, despite its rare occurrence, the diagnostic possibility of angiolipoma considering a benign breast tumor should be raised when other main diagnoses have been ruled out.

We expect that the information in this article can contribute scientifically with other professionals.

ACKNOWLEDGEMENTS

The authors would like to thank the patient for allowing the elaboration of this case report, as well as the entire staff of the hospital and the Ethics Committee in charge, who collaborated with the performance of this analysis.

AUTHORS' CONTRIBUTION

NSQ: Methodology, Project administration, Writing – review & editing. VS: Investigation, Writing – original draft, Writing – review & editing. MBC: Data curation, Formal Analysis, Writing – review & editing.

REFERENCES

1. Cheung YC, Wan YL, Ng SH, Ng KK, Lee KF, Chao TC. Angiolipoma of the breast with microcalcification. Mammographic, sonographic, and histologic appearances. Clin Imaging. 1999;23(6):353-5. https://doi.org/10.1016/S0899-7071(00)00165-0
2. Kryvenko ON, Chitale DA, VanEgmond EM, Gupta NS, Schultz D, Lee MW. Angiolipoma of the female breast: clinicomorphological correlation of 52 cases. Int J Surg Pathol. 2011;19(1):35-43. https://doi.org/10.1177/1066896910385679
3. Noel JC, Van Geertruyden J, Engohan-Aloghe C. Angiolipoma of the breast in a male: a case report and review of the literature. Int J Surg Pathol. 2011;19(6):813-6. https://doi.org/10.1177/1066896909350467
4. Weinstein SP, Conant EF, Acs G. Case 59: Angiolipoma of the breast. Radiology. 2003;227(3):773-5. https://doi.org/10.1148/radiol.2273011418
5. Darling ML, Babagbemi TO, Smith DN, Brown FM, Lester SC, Meyer JE. Mammographic and sonographic features of angiolipoma of the breast. Breast J. 2000;6(3):166-70. https://doi.org/10.1046/j.1524-4741.2000.99064.x

This is an open access article distributed under the terms of the Creative Commons license.