ORIGINAL ARTICLE
https://doi.org/10.29289/2594539420220029

Benefits of a standardized protocol for axillary management after neoadjuvant chemotherapy in a single center.

Marina de Paula Canal[1]*, Caroline Gomes de Almeida Rocha[1], Almir Galvão Vieira Bitencourt[2], Marina Sonagli[1], Cynthia Aparecida Bueno de Toledo Osório[3], Monique Celeste Tavares[4], Solange Moraes Sanches[4], Fabiana Baroni Alves Makdissi[1]

ABSTRACT

Introduction: The axillary lymph node status is one of the most important prognostic factors in breast cancer. For locally advanced tumors, neoadjuvant chemotherapy favors higher rates of breast lumpectomy and downstaging tumor burden of axilla. The aim of this study was to evaluate the use of a standardized image-guided protocol after neoadjuvant chemotherapy to enable sentinel node dissection in patients with axillary downstaging, avoiding axillary dissection. **Methods:** Retrospective cohort study of data collected from medical records of patients who underwent neoadjuvant chemotherapy in a single center, from January 2014 to December 2018. The protocol comprises the placement of a metal clip in positive axillary lymph node, in patients with up to two clinically abnormal lymph nodes presented on imaging. After neoadjuvant chemotherapy, and once a radiologic complete response was achieved, sentinel node dissection was performed using blue dye and radiotracer. Axillary dissection were avoided in patients whose clipped sentinel node were negative for metastasis and in patients with three identified and negative sentinel node dissection. **Results:** A total of 471 patients were analyzed for this study: 303 before and 165 after the implementation of the protocol; 3 cases were excluded. The rate of sentinel node dissection in clinical nodes positive patients was statistically higher in this group when compared to patients treated before the protocol implementation (22.8% vs. 40.8%; p=0.001). Patients with triple negative and HER2-positive tumors underwent sentinel node dissection more frequently when compared to luminal tumors (p=0.03). After multivariate analysis, the variables that were associated with a greater chance of performing sentinel node dissection were clinical staging, type of surgery performed and implementation of the axillary assessment protocol. **Conclusions:** The results showed that the use of an easily and accessible image-guided protocol can improve sentinel node dissection in selected patients, even if the lymph node was positive previously to neoadjuvant treatment.

KEYWORDS: axillary lymph node; neoadjuvant chemotherapy; downstaging; standardized protocol.

INTRODUCTION

Axillary lymph node status is one of the most important prognostic factors in breast cancer. For locally advanced tumors, neoadjuvant chemotherapy (NACT)[1] shows no difference in overall survival (OS) or in specific-cancer survival (SCS) when compared to adjuvant chemotherapy[2], but it favors higher rates of breast lumpectomy and downstaging tumor burden of axilla[3]. In addition, the current indication for NACT in breast cancer allows for *in vivo* evaluation of the tumor for systemic treatment, which has an important prognostic value for certain subtypes, such as triple negative and HER2-positive.

Axillary lymph node dissection (ALND) is related to an increased risk of adverse events, such as lymphedema (14%), limitation of upper limb mobility (28%), and neuropathic pain (31%)[4].

The three main clinical, prospective and randomized studies that assessed axillary management after NACT (ACOSOG Z1071[5], SENTINA arm C[6], and SN FNAC)[7] mainly included cT1, cT2, and cN1 patients who underwent sentinel lymph node

[1]Hospital A.C.Camargo Cancer Center, Department of Mastology – São Paulo (SP), Brazil.
[2]Hospital A.C.Camargo Cancer Center, Image Department – São Paulo (SP), Brazil.
[3]Hospital A.C.Camargo Cancer Center, Department of Pathology – São Paulo (SP), Brazil.
[4]Hospital A.C.Camargo Cancer Center, Department of Clinical Oncology – São Paulo (SP), Brazil.
***Corresponding author:** marina.canal@accamargo.org.br, mpcanal738@gmail.com
Conflict of interests: nothing to declare. **Funding:** none.
Received on: 07/26/2022. **Accepted on:** 10/31/2022.

dissection (SLND), followed by ALND. The detection of sentinel lymph nodes (SLNs) was possible in 80.0%–92.7% of clinical nodes positive (cN+) patients who had a clinical response. The false negative rate (FNR) ranged from 12.3% to 14.2%. However, when three SLNs were removed, the FNR dropped to 4.9%–9.1% (using radiotracer detection method) and 8.6%–10.8% (using blue dye)[5-7].

The target axillary dissection (TAD) has been adopted as a strategy to reduce the FNR in cN+ patients. In this technique, the target lymph node is marked with a metal clip at the time of biopsy, before NACT and up to five days before surgery. An additional ultrasound (US) is then performed, during which the clipped lymph node receives radioactive "seeds"[8] or tracers, and blue dye, ensuring accurate SLND. With this technique, FNRs as low as 2% have been observed, and in 77% of cases the marked lymph node corresponded to the SLN[9]. However, TAD has not been universally adopted because of the difficulties related to pre- and intraoperative localization of previously marked lymph nodes which had shown complete response to NACT[1].

To minimize the FNR in relation to axillary dissection, we developed a standardized protocol in our institution for clipping positive lymph nodes prior to NACT combined with post-NACT axillary management. The objective of this study was to show that it is possible to prevent ALND in clinically negative patients after NACT, using an image-guided protocol that is easily accessible to doctors and patients from other centers.

METHODS

The present retrospective cohort study, approved by the institutional review board (IRB) of a single-center, included patients who underwent NACT from January 2014 to December 2018. Data collected considered molecular subtype of the tumor, clinical stage (T or N) prior to NACT, type of surgery (mastectomy or lumpectomy), and type of dissection (ALND, SLND, or SLND followed by ALND).

The elegible patients were diagnosed with invasive breast carcinoma and submitted to NACT; underwent biopsy or review of biopsy pathology slides at the institution; and received all treatment (chemotherapy and surgery) at the institution. Male patients were excluded as well as those with inflammatory carcinoma, metastatic, recurrent, or bilateral tumors.

All the elegible were examined before and after the implementation of the standardized protocol for axillary treatment after NACT. There were three possible protocols, depending on the lymph node status of each patient:

1. clinically negative axilla;
2. up to two clinically positive lymph nodes on imaging prior to NACT, which were clipped; and
3. up to two clinically positive lymph nodes prior to NACT, which were not clipped. This protocol is described on Figure 1.

Clinically positive lymph nodes were defined as lymph nodes showing cortical thickening, absence of fatty hilum, and round or oval shape on imaging exams, especially ultrasound. Fine needle

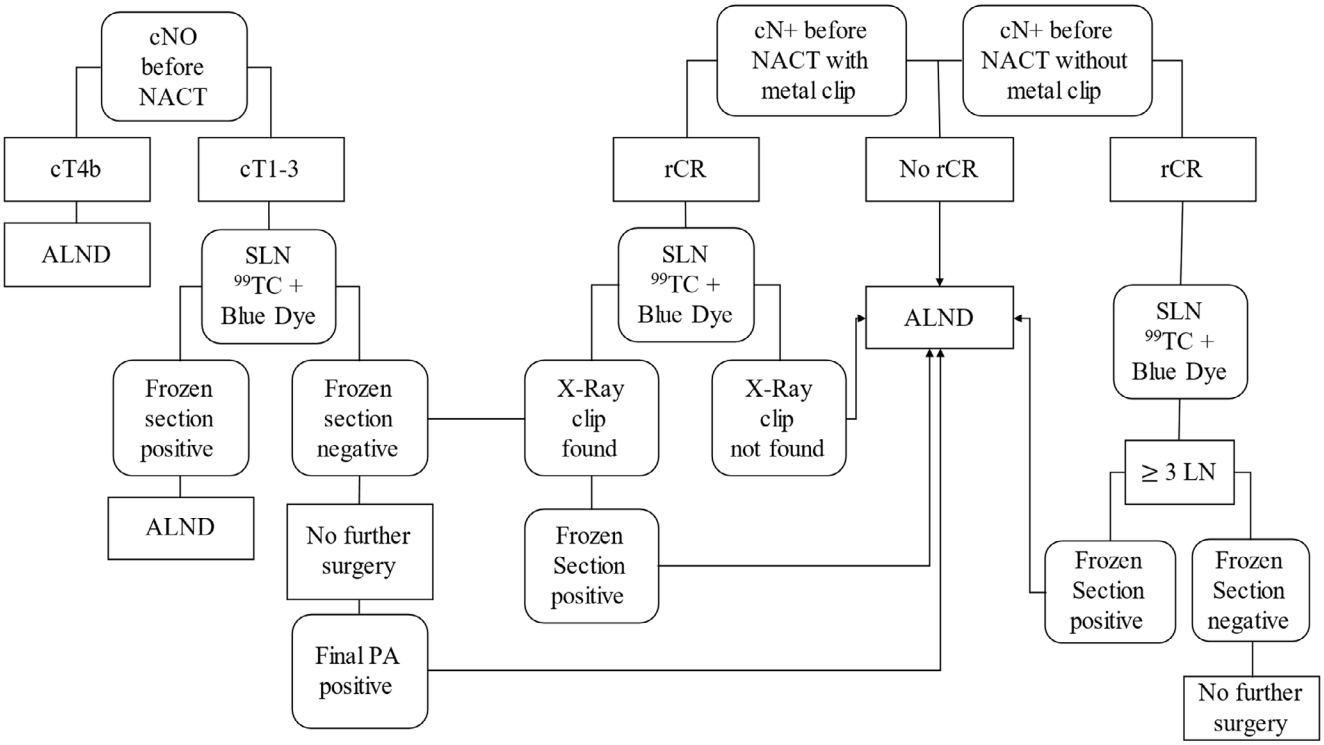

cN0: patients without suspect lymph nodes; NACT: neoadjuvant chemotherapy; ALND: axillary lymph node dissection; SLN: sentinel lymph node; 99Tc: Technecium-99m; PA: pathology analysis; cN+: clinical nodes positive; rCR: radiological complete response; LN: lymph node.

Figure 1. Protocol of axillary management after neoadjuvant chemotherapy.

aspiration biopsy (FNAB) was performed in suspicious lymph nodes and a metal clip was placed when FNAB confirmed metastasis from breast carcinoma. ALND was performed in patients with two or more clinically positive lymph nodes prior to NACT, patients with persistent disease after NACT (clinical or radiological), and patients whose initial stage was T4 or was inflammatory and had no SLN migration. SLND was performed in patients with up to two clinically positive lymph nodes prior to NACT, and patients who had had a complete clinical and radiological response after NACT and SLN migration. Clinical response was defined as non-palpable lymph nodes after NACT and radiological response as disappearance of abnormal lymph nodes.

SLN marking was performed on the eve of surgery through injection of Technecium-99m (^{99}Tc)-labelled radiotracer into the breast, close to the tumor area, with lymphoscintigraphy to evaluate migration. Marking with blue dye was performed during surgery through a subdermal injection into the ipsilateral breast in the periareolar or superolateral quadrant, depending on the surgeon's preference.

We did not mark the clipped lymph node before surgery, only the SLN and, when removing a lymph node marked by ^{99}Tc or blue dye, a portable X-ray (Faxitron®) or mammography confirmed the presence of the clip for protocol validation (Figure 2).

When the clipped lymph node could not be found, either because it was not the sentinel or due to clip migration, axillary lymphadenectomy was performed.

Pathological analysis (frozen section) of lymph nodes after NACT[10] was performed in three parts:

1. *Macroscopic examination*. In the perioperative examination, SLNs were sliced transversely to a thickness of 2 mm and examined by a pathologist to identify the presence of any white and hard areas suggestive of residual lymph node metastasis. All slices of lymph node tissue were fixed in 10% buffered formalin and included in one or more paraffin blocks for the definitive histological evaluation.
2. *Microscopic evaluation*. In the microscopic evaluation, a pathologist measured the linear dimension of the largest metastatic focus and described the presence of a possible area of pathological response, characterized by fibrosis, hemorrhage, accumulations of macrophages and a decrease in the lymph node parenchyma. Additional sections of 4-µm thickness were stained with hematoxylin-eosin and analyzed by a pathologist for the presence of isolated cells, or a group of atypical epithelial cells compatible with residual neoplasia, which would determine ALND. The metal clip area was also described, characterized by foreign body-type gigantocellular reaction and lymphocytic infiltrate around amorphous acidophilic material, compatible with the gel shell present in the clips used.
3. *Tumor presence*. The presence of axillary nodal tumor deposits of any size, including isolated tumor cells, eliminated a complete pathological response. Finally, the number of compromised lymph nodes was counted and classified to obtain the residual cancer burden (RCB) index and classification[11].



Figure 2. Sentinel lymph node surgical specimen: (A) sentinel lymph node stained with blue dye; (B) X-ray photo showing metal clip inside the sentinel lymph node.

Descriptive statistical methods were used for statistical analysis and the results of categorical variables were expressed as frequencies and percentages. Statistical analysis was performed using Pearson's χ^2 test with Yates correction or Fisher's exact test, when indicated. The level of significance adopted was 5% ($p \leq 0.05$).

RESULTS

A total of 471 female patients aged 24–87 years were analyzed, and 3 patients were excluded due to missing data on medical record. Included patients were categorized according to the TNM staging (cT1–cT4, cN0, cN+) and the molecular subtype (luminal [estrogen and progesterone receptor positive and HER2-negative], HER2 overexpressing, or triple negative) (Table 1).

Table 1. Characteristics of patients according to TNM staging and molecular subtype.

T and N and molecular subtype		n	%
T	cT1	36	7.7
	cT2	173	37.0
	cT3	141	30.2
	cT4	117	25.1
	Total	467	100.0
No data		4	
N	cN0	76	16.5
	cN+	385	83.5
	Total	461	100.0
No data		10	
Molecular subtype	Luminal (ER+, PR+, HER2-negative)	210	44.9
	HER 2 overexpressing	122	26.1
	Triple negative	136	29.1
	Total	468	100.0
No data		3	
Total		471	100.0

cN0: patients without suspect of lymph nodes; cN+: clinical nodes positive; ER: estrogen receptor; PR: progesterone receptor; HER2: Human Epidermal growth factor Receptor-type 2

Of the total, 295 underwent mastectomy (simple, radical modified, or skin-sparing) and 176 underwent breast-conserving surgeries (quadrantectomy or lumpectomy). ALND was performed in 303 patients, SLND in 156, and SLND followed by ALND in 9. In the period from 2014 to 2017, prior to the implementation of the standardized protocol for pre-NACT axillary management, 303 patients were included: 290 cN+ and 13 clinical nodes negative (cN-). Of these 290, 77% underwent ALND and 23% underwent SLND. Of the 13 cN- patients, 76% underwent ALND and 24% underwent SLND (Figure 3).

As of 2017, a standardized protocol for pre-NACT axillary management was instituted, and thereafter 165 patients were included. Of these, 67 were axillary clinically negative, 49 underwent SLND, and 18 underwent ALND. Additionally, 98 patients were classified as cN+ based on physical examination and imaging. Of them, 58 underwent ALND and 40 SLND (Figure 4). Of the 98 patients, 74 were confirmed by FNAB positive for malignancy and 24 were negative.

Prior to implementation of the standard protocol, of the patients who were clinically positive, 77.2% underwent ALND and 22.8% underwent SLND; after implementation, 59.2% underwent ALND and 40.8% SLND. The increase in SLND after protocol implementation was statistically significant (p=0.01) (Figure 5).

Rates of SLND differed across molecular subtypes. Patients with tumors that were triple negative underwent SLND most frequently (44%), followed by HER2 overexpressing (32%), and luminal (26%). The difference between triple negative and luminal patients was statistically significant (p=0.03). After multivariate analysis, the variables that were associated with a greater chance of performing SLND were clinical staging, type of surgery performed and implementation of the axillary assessment protocol (Table 2).

In the post-implementation of the standard protocol group, we had observed 8 patients with systemic progression, 3 with locoregional progression and 154 without evidence of disease, in the period 2018 to 2022.

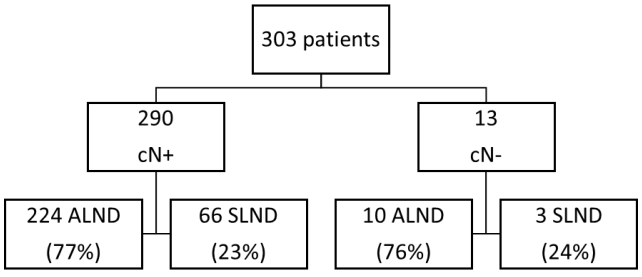

cN+ clinical nodes positive; cN- clinical nodes negative; ALND: axillary lymph node dissection; SLND: sentinel lymph node dissection.

Figure 3. Division of patients who were evaluated from 2014 to 2017, before implementation of the standardized protocol.

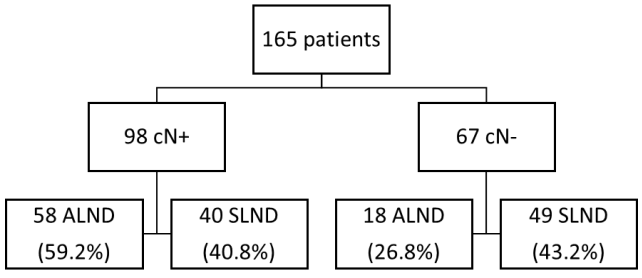

cN+ clinical nodes positive; cN- clinical nodes negative; ALND: axillary lymph node dissection; SLND: sentinel lymph node dissection.

Figure 4. Patients who were clinically positive nodes after protocol change.

DISCUSSION

In the present study we described a standardized image-guided protocol for post-NACT axillary management which increases the efficacy of TAD and reduces the FNR of SLND.

NACT is an important tool for the treatment of certain breast cancers because it not only reduces tumor burden by initially treating the systemic micrometastatic disease, but has also been shown to increase the rate of conservative surgeries in patients who would not otherwise be candidates[12-14]. NACT also plays a role in axillary downstaging, improving outcomes of clinically positive patients who underwent chemotherapy prior to SLND. The present study similarly found that, in the 98 patients who presented clinically positive axilla, NACT avoided lymphadenectomy in 40.8% of cases. This result is nearly identical to that of Mamtani et al., who reported in a prospective study that 70% of clinically positive patients were eligible for SLND after NACT and 48% were able to avoid ALND[15]. Together, both studies demonstrated the role of NACT in reducing the need for ALND among patients with lymph node metastasis.

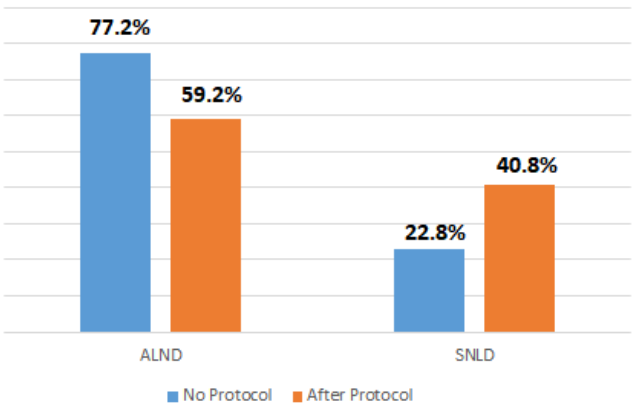

Figure 5. The rate of sentinel lymph node dissection in clinical nodes positive patients was statistically higher in this group when compared to patients treated before the protocol implementation (22.8% vs. 40.8%; p=0.001).

Table 2. Multivariate analysis of clinicopathological variables to perform sentinel lymph node dissection vs. axillary lymph node dissection in breast cancer patients undergoing neoadjuvant chemotherapy.

	Categories	Coefficient	Std. Error	HR	95%CI		p-value
					Inferior	Superior	
Subtype	Luminal			Ref			
	HER-2	0.376	0.292	1.457	0.822	2.582	0.197
	Triple-negative	0.470	0.285	1.600	0.915	2.798	0.099
Axillary status before NACT	cN0			Ref			
	cN+	0.646	0.287	1.907	0.892	4.076	0.096
Clinical Status	I			Ref			
	II	2.526	0.759	12.497	2.824	55.304	0.001
	III	1.597	0.259	4.937	2.973	8.201	0.0001
Surgery dissection	Mastectomy			Ref			
	Lumpectomy	0.880	0.240	2.411	1.506	3.862	0.0001
Standardized protocol	before			Ref			
	after	1.265	0.288	3.542	2.014	6.229	0.0001

Std.: standard; HR: hazard ratio; NACT: neoadjuvant chemotherapy; cN0: patients without suspect of lymph nodes; cN+: clinical nodes positive.

TAD is not feasible in many hospitals of our country due to its costs. Therefore, we created a protocol that adapts TAD to our reality, decreasing ALND rates combined with a lower FNR.

The use of a standardized protocol for axilla management proved to be useful also for patients with a cN+ prior to NACT that had a complete radiological response, since the rate of SLND raised 40% and the rate of ALND dropped 18% after the implementation of our protocol.

Considering the performance of lumpectomy after NACT, Bonadonna and Veronesi reported that NACT reduced large tumors to less than 3 cm in 81% of patients, allowing lumpectomy instead of radical mastectomy in 50%–75% of patients for whom mastectomy was initially indicated[13-14].

Regarding molecular subtypes, we observed that most of patients were ER+, triple negative and HER2-positive, but the group who were triple negative underwent significantly more SLND than those in the luminal (HER2-negative) subgroup.

This study has limitations inherent to its retrospective design. First, the medical records were not standardized, especially regarding axillary status prior to the implementation of institutional protocol in 2017. In addition, the relatively small number of patients in the sample may have limited statistical analyses. Despite this, the present study demonstrates the effectiveness in implementing a standardized image-guided protocol for axillary management before and after NACT. The institutional protocol used was created in order to reduce the number of false-negative results of SLND and minimize technical limitations of the TAD that make its routine implementation unfeasible, such as difficulty in locating the clipped lymph node, especially when it has a complete response to treatment[17].

CONCLUSIONS

The results of this study showed an increase in the frequency of SLND after implementation of a standardized image-guided protocol for axilla management after NACT in breast cancer patients, at a single medical center where TAD is not available. We know that there are numerous searches for quality of treatment and reduction of damage caused by unnecessary treatments. Our observation was that the design in detail of all the best options for patients after NACT was responsible for improving care for our patients, even still having adequate information in cases of additional therapeutic possibility in patients with partial response.

ACKNOWLEDGMENTS

We thank Janaina Naiara Germano for her support in statistics analysis, Silvana Santos for her assistance on the first data research and Carley Karsten for the English review.

AUTHORS' CONTRIBUTION

MPC: Data curation, Investigation, Writing – original draft, Writing – review & editing. CGAR: Data curation, Writing – original draft. AB: Formal Analysis, Methodology, Writing – review & editing. MS: Writing – original draft, Writing – review & editing. CABTO: Validation, Writing – original draft. MCT: Data curation. SMS: Supervision, Writing – review & editing. FBAM: Conceptualization, Project administration, Supervision, Writing – review & editing.

REFERENCES

1. Nguyen TT, Hoskin TL, Day CN, Degnim AC, Jakub JW, Hieken TJ, et al. Decreasing use of axillary dissection in node-positive breast cancer patients treated with neoadjuvant chemotherapy. Ann SurgOncol. 2018;25(9):2596-602. https://doi.org/10.1245/s10434-018-6637-9
2. Rubovszky G, Horváth Z. Recent advances in the neoadjuvant treatment of breast cancer. J Breast Cancer. 2017;20(2):119-31. https://doi.org/10.4048/jbc.2017.20.2.119
3. Haffty BG, McCall LM, BallmanKV, McLaughlin S, Jagsi R, Ollila DW, et al. Patterns of local-regional management following neoadjuvant chemotherapy in breast cancer: Results from ACOSOG Z1071 (Alliance). Int J Radiat Oncol Biol Phys. 2016;94(3):493-502. https://doi.org/10.1016/j.ijrobp.2015.11.005
4. Fleissig A, Fallowfield LJ, Langridge CI, Johnson L, Newcombe RG, Dixon JM, et. al. Post-operative arm morbidity and quality of life. Results of the ALMANAC randomised trial comparing sentinel node biopsy with standard axillary treatment in the management of patients with early breast cancer. Breast Cancer Res Treat. 2006;95(3):279-93. https://doi.org/10.1007/s10549-005-9025-7
5. Boughey JC, Suman VJ, Mittendorf EA, Ahrendt GM, Wilke LG, Taback B, et. al. Sentinel lymph node surgery after neoadjuvant chemotherapy in patients with node-positive breast cancer: the ACOSOG Z1071 (Alliance) clinical trial. JAMA. 2013;310(14):1455-61. https://doi.org/10.1001/jama.2013.278932
6. Kuehn T, Bauerfeind I, Fehm T, Fleige B, Hausschild M, Helms G, et al. Sentinel-lymph-node biopsy in patients with breast cancer before and after neoadjuvant chemotherapy (SENTINA): a prospective, multicentre cohort study. Lancet Oncol. 2013;14(7):609-18. https://doi.org/10.1016/S1470-2045(13)70166-9
7. Boileau JF, Poirier B, Basik M, Holloway CM, Gaboury L, Sideris L, et. al. Sentinel node biopsy after neoadjuvant chemotherapy in biopsy-proven node-positive breast cancer: the SN FNAC study. J Clin Oncol. 2015;33(3):258-64. https://doi.org/10.1200/JCO.2014.55.7827
8. Pilewskie M, Morrow M. Axillary Nodal Management Following Neoadjuvant Chemotherapy: A Review. JAMA Oncol. 2017;3(4):549-55. https://doi.org/10.1001/jamaoncol.2016.4163
9. Caudle AS, Yang WT, Krishnamurthy S, Mittendorf EA, Black DM, Gilcrease MZ, et. al. Improved axillary evaluation following neoadjuvant therapy for patients with node-positive breast cancer using selective evaluation of clipped nodes: implementation of targeted axillary dissection. J Clin Oncol. 2016;34(10):1072-8. https://doi.org/10.1200/JCO.2015.64.0094
10. Symmans WF, Peintinger F, Hatzis C, Rajan R, Kuerer H, Valero V, et at. Measurement of residual breast cancer burden to predict survival after neoadjuvant chemotherapy. J Clin Oncol. 2007;25(28):4414-22. https://doi.org/10.1200/JCO.2007.10.6823
11. Osório CABT, Chaves Júnior MA, Soares FA. Assessment of pathological response in breast cancer after neoadjuvant chemotherapy: standardization of adapted protocol. J Bras Patol Med Lab. 2012;48(6): 447-53. https://doi.org/10.1590/S1676-24442012000600010
12. Mamouch F, Berrada N, Aoullay Z, El Khanoussi B, Errihani H. Inflammatory breast cancer: a literature review. World J Oncol. 2018;9(5-6):129-35. https://doi.org/10.14740/wjon1161
13. Mauriac L, Durand M, Avril A, Dilhuydy JM. Effects of primary chemotherapy in conservative treatment of breast cancer patients with operable tumors larger than 3 cm. Results of a randomized trial in a single centre. Ann Oncol. 1991;2(5):347-54. https://doi.org/10.1093/oxfordjournals.annonc.a057953
14. Bonadonna G, Veronesi U, Brambilla C, Ferrari L, Luini A, Greco M, et al. Primary chemotherapy to avoid mastectomy in tumors with diameters of three centimeters or more. J Natl Cancer Inst. 1990;82(19):1539-45. https://doi.org/10.1093/jnci/82.19.1539
15. Mamtani A, Barrio AV, King TA, Van Zee KJ, Plitas G, Pilewskie M, et al. How often does neoadjuvant chemotherapy avoid axillary dissection in patients with histologically confirmed nodal metastases? results of a prospective study. Ann Surg Oncol. 2016;23(11):3467-74. https://doi.org/10.1245/s10434-016-5246-8
16. Schwartz GF, Tannebaum JE, Jernigan AM, Palazzo JP. Axillary sentinel lymph node biopsy after neoadjuvant chemotherapy for carcinoma of the breast. Cancer. 2010 Mar 1;116(5):1243-51. https://doi.org/10.1002/cncr.24887
17. Ecanow JS, Abe H, Newstead GM, Ecanow DB, Jeske JM. Axillary staging of breast cancer: what the radiologist should know. Radiographics. 2013;33(6):1589-612. https://doi.org/10.1148/rg.336125060

This is an open access article distributed under the terms of the Creative Commons license.