CASE REPORT
https://doi.org/10.29289/2594539420220016

De novo gastric metastasis from invasive lobular carcinoma of the breast: report of three cases and literature review

Jessica Gonzalez Suerdieck[1], Juliana Alves Souza[1], Mateus Mattioni[1], Almir Galvão Vieira Bitencourt[1]*

ABSTRACT

Invasive lobular carcinoma is the second most common subtype of invasive breast cancer and presents with an unusual metastatic pattern. Its gastric metastasis mimics primary adenocarcinoma and the differentiation between them is difficult but primordial for proper treatment. The aim of this study is to report three cases of de novo Invasive lobular carcinoma of the breast, diagnosed with gastric metastasis at presentation. Neither of the patients complained about breast symptoms before the diagnosis. The final diagnosis was made only by comparing breast and gastric samples.

KEYWORDS: gastric metastasis; breast neoplasms; invasive lobular carcinoma; ultrasound; magnetic resonance imaging; 18F-FDG PET/CT.

INTRODUCTION

Invasive lobular carcinoma (ILC) is the second most common subtype of invasive breast cancer, accounting for about 5–15% of cases[1-3]. It has a typical histopathological appearance of poorly cohesive cells[1].

ILC is associated with the absence of E-cadherin that influences the tendency to spread among collagen fibers with less desmoplastic response and becomes more likely to migrate to distant places of the primary tumor[4,5]. This increases the rates of multicentricity and bilaterality and results in an unusual metastatic[3,6-8].

Although rare, metastatic spread to the stomach stands out by being highly related to ILC and very difficult to differentiate from primary adenocarcinoma[2,3,5-12]. For this reason, previous studies questioned the real frequency of gastric metastasis from breast cancer, which might be underestimated[13].

The aim of this study is to report three cases of de novo ILC of the breast, diagnosed with gastric metastasis at presentation, and to review the literature about the pattern of metastasis.

CASE REPORTS

Case 1

A 70-year-old woman presented with gastrointestinal (GI) symptoms developed in a 2-month period. An upper GI (UGI) endoscopy demonstrated a diffuse infiltrative lesion with thickening and rigidity of the gastric walls (Figure 1A), suggestive of linitis plastica. An initial histopathological study revealed a poorly differentiated adenocarcinoma with poorly cohesive cells. 18F-FDG PET/CT showed diffuse uptake of the gastric wall thickening (Figure 1B) along with focal uptakes of multiple lymph nodes, irregular lesions in the right breast (Figure 1C), and bone lesions. Ultrasound showed a hypoechoic nodule with an irregular shape and indistinct margins in the upper-outer quadrant of the right breast (Figure 1D). A core biopsy was performed, and the histopathological study revealed a pleomorphic ILC. After comparing the samples, the final diagnosis was a metastasis of breast carcinoma.

[1]Hospital A.C. Camargo Cancer Center, Department of Imaging – São Paulo (SP), Brazil.
Corresponding author: almirgvb@yahoo.com.br
Conflicts of interest: nothing to declare. **Funding:** none.
Received on: 06/01/2022. **Accepted on:** 06/21/2022.

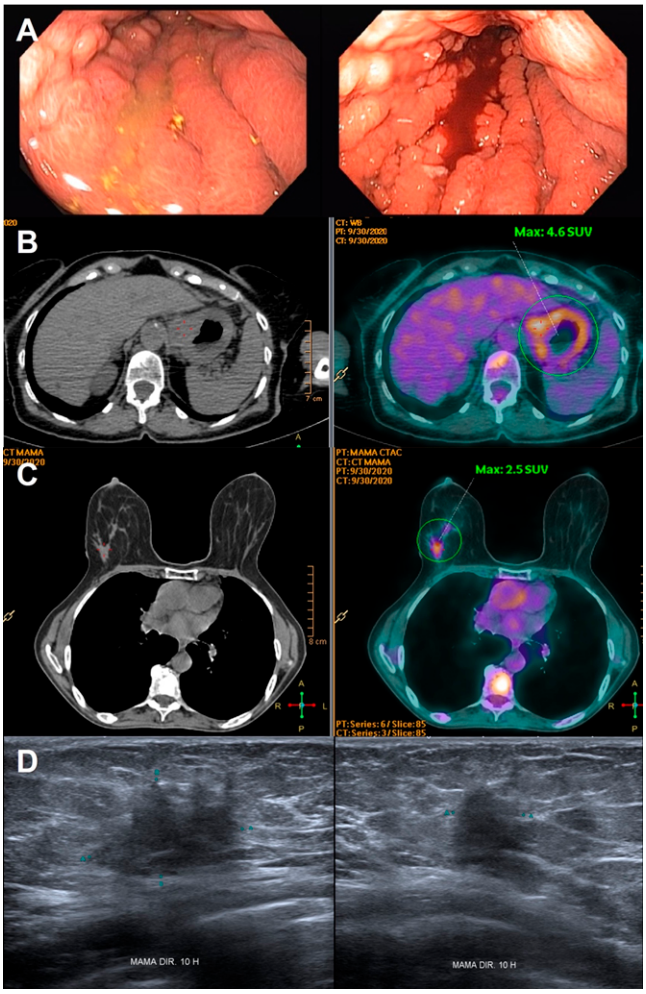

Figure 1. (A) UGI endoscopy showing diffuse infiltrative lesion with thickening of the gastric walls. (B) 18F-FDG PET/CT with diffuse uptake of the gastric wall thickening. (C) 18F-FDG PET/CT with irregular lesion in the right breast. (D) Ultrasound revealing a hypoechoic nodule with irregular shape and indistinct margins in the upper-outer quadrant of the right breast.

Case 2

A 42-year-old woman presented with GI symptoms developed in 3 months. An UGI endoscopy showed diffuse thickening and rigidity of the gastric walls (Figure 2A). Abdominal magnetic resonance imaging (MRI) demonstrated concentric thickening of the antrum and gastric body along with mesenteric lymph nodes, liver lesions, and diffuse bone lesions, all of which showed an increased 18F-FDG uptake in PET/CT (Figure 2B). The gastric histopathological study demonstrated infiltration by carcinoma with discohesive cells with probable mammary origin. The patient denied any breast symptoms. Ultrasound showed a hypoechoic nodule with an irregular shape and an indistinct margin in the lower-inner quadrant (Figure 2C). A core biopsy was performed in the nodule of the right breast, and the histopathological study revealed classic ILC.

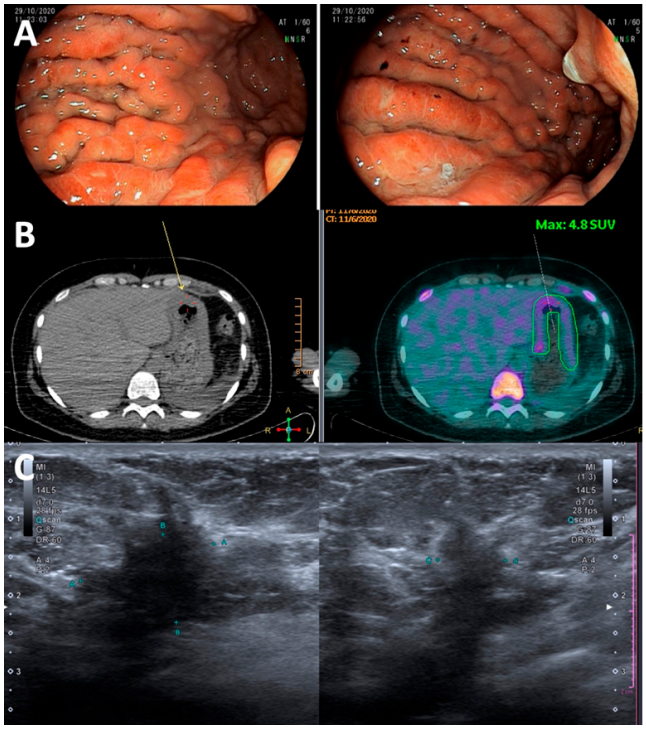

Figure 2. (A) UGI endoscopy showing diffuse thickening and rigidity of the gastric walls. (B) 18F-FDG PET/CT showing uptake along the concentric thickening of the antrum and gastric body. (C) Ultrasound revealing a hypoechoic nodule with irregular shape and indistinct margin in the right breast.

Case 3

A 53-year-old woman presented with epigastric pain developed in 3 months. An UGI endoscopy showed an elevated lesion in the distal body of the stomach that was biopsied, and the result was a poorly differentiated adenocarcinoma, but the immunohistochemical analysis suggested the possibility of metastasis from ILC. Breast MRI showed suspicious focal nonmass enhancements and osteoblastic lesions in both breasts (Figure 3A). PET/CT revealed focal uptakes in two areas in the left breast and ipsilateral lymph nodes. Second-look ultrasound showed discrete hypoechoic areas (Figure 3B), which corresponded to the PET/CT findings, and the core biopsy revealed classic ILC. The patient also had two ulcerated lesions in the caecum and descending colon seen on colonoscopy. After the diagnosis of ILC, a new evaluation of the previous biopsies of the GI tract was made and all of them were metastasis.

DISCUSSION

ILC is the second most common type of breast cancer[1-3] and shows a higher rate of multiplicity and bilaterality as presented by our patients.

The metastatic involvement of the GI tract by breast cancer is rare and usually not remembered in daily practice[3,5,8-12]. The most

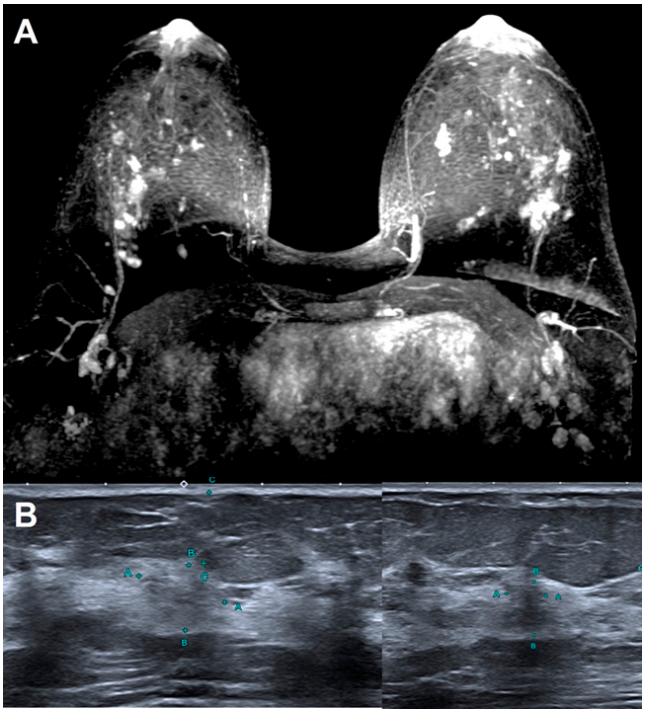

Figure 3. (A) Breast MRI showing suspicious focal nonmass enhancements in both breasts. (B) Second-look ultrasound showing discrete hypoechoic areas in the left breast, which corresponded to PET/CT findings.

common spread is to the stomach with frequencies ranging from 0.3% to 35%, followed by the colon[1-3,5,9,11]. Considering metastatic breast involvement in the stomach, ILC accounts for 80% of the cases[5,7,9-11,13].

Gastric metastasis of breast cancer usually appears years after the primary lesion treatment, i.e., between 2 and 7 years[2,3,5,6,9-11]. However, the patients in this study were diagnosed with gastric lesions at the same time as primary cancer. They were all initially considered to have primary gastric cancer and then investigated for breast lesions. Two of them did not even complain of breast symptoms.

This pattern of metastasis mimics the primary adenocarcinoma because it has similar symptoms, imaging and endoscopic features, and histopathological findings[2,3,5-7,9-12]. This implies that the correct diagnosis requires a high level of suspicion. Usually, when there is a metastatic gastric lesion from breast cancer, concurrent metastases are present, mainly in the skeleton, liver, and lungs[3,6,9-11]. In all of our cases, both bones and lymph nodes were involved.

The most common macroscopic appearance is linitis plastica[3,5,6,8,11,12]. Two of our cases manifested this form of tumor infiltration in the stomach, and all of them manifested nonspecific digestive symptoms.

The histopathological findings are similar between primary and metastatic lesions and, above all, the ILC may produce a signet ring morphology that is the most common pattern of primary adenocarcinoma[3,5,9,10]. For a definitive confirmation, a detailed immunohistochemical analysis may be needed[3,4,6,8,11]. Metastatic breast carcinoma is usually positive for CK7, GCDFP-15, and estrogen and progesterone receptors, and negative for CK20[3,4,6,8,11]. However, CK7 and hormonal receptors may be expressed in gastric adenocarcinomas[9,11]. The absence of E-cadherin is significantly related to metastatic breast carcinoma[9,11].

Histologic comparison of the endoscopic biopsies with the breast carcinoma specimen is highly recommended[11,13]. All our patients first had a diagnosis of primary gastric adenocarcinoma and, after comparison, the diagnosis changed.

The importance of distinguishing primary gastric adenocarcinoma from metastatic breast ILC is that the two diagnoses lead to divergent treatments: while the metastasis is treated using systemic therapies (chemotherapy and/or hormonal therapy), the primary cancer is treated by surgery[2,6,8,9,11].

CONCLUSIONS

Distinguishing primary gastric adenocarcinoma from metastatic breast ILC is essential, considering that the two diagnoses lead to divergent treatments. Therefore, this entity needs to be remembered as a differential diagnosis in clinical practice.

AUTHORS' CONTRIBUTIONS

JGS: Conceptualization, Investigation, Methodology, Writing – original draft, Writing – review & editing. JAS: Conceptualization, Methodology, Writing – review & editing. MM: Investigation, Methodology, Writing – review & editing. AGVB: Conceptualization, Methodology, Writing – review & editing.

REFERENCES

1. Inoue M, Nakagomi H, Nakada H, Furuya K, Ikegame K, Watanabe H, et al. Specific sites of metastases in invasive lobular carcinoma: a retrospective cohort study of metastatic breast cancer. Breast Cancer. 2017;24(5):667-72. https://doi.org/10.1007/s12282-017-0753-4

2. Clinton LK, Plesec T, Goldblum JR, Hajifathalian K, Downs-Kelly E, Patil DT. Specific histopathologic features aid in distinguishing diffuse-type gastric adenocarcinoma from metastatic lobular breast carcinoma. Am J Surg Pathol. 2020;44(1):77-86. https://doi.org/10.1097/PAS.0000000000001341

3. El-Hage A, Ruel C, Afif W, Wissanji H, Hogue JC, Desbiens C, et al. Metastatic Pattern of Invasive Lobular Carcinoma of the Breast — Emphasis on Gastric Metastases. Journal of Surgical Oncology. 2016;114(5):543-47. https://doi.org/10.1002/jso.24362

4. Reed AEM, Kutasovic JR, Lakhani SR, Simpson PT. Invasive lobular carcinoma of the breast: morphology, biomarkers and 'omics. Breast Cancer Research. 2015;17(1):12. https://doi.org/10.1186/s13058-015-0519-x

5. Eo WK. Breast cancer metastasis to the stomach resembling early gastric cancer. Cancer Res Treat. 2008;40(4):207-10. https://doi.org/10.4143/crt.2008.40.4.207

6. Dória MT, Maesaka JY, Martins Filho SN, Silveira TP, Boufellia G, Siqueira SAC, et al. Gastric metastasis as the first manifestation of an invasive lobular carcinoma of the breast. Autopsy and Case Reports. 2015;5(3):49-53. https://doi.org/10.4322/acr.2015.018

7. Hong J, Kim Y, Cho J, Lim SW, Park SE, Kim HK, et al. Clinical features and prognosis of breast cancer with gastric metastasis. Oncology letters. 2019;17(2):1833-41. https://doi.org/10.3892/ol.2018.9754

8. Yagi Y, Sasaki S, Yoshikaw A, Tsukioka Y, Fukushima W, Fujimura T, et al. Metastatic gastric carcinoma from breast cancer mimicking primary linitis plastica: a case report. Oncology Letters. 2015;10:3483-7. https://doi.org/10.3892/ol.2015.3788

9. Pectasides D, Psyrri A, Pliarchopoulou K, Floros T, Papaxoinis G, Skondra M, et al. Gastric metastases originating from breast cancer: repost of 8 cases and review of the literature. Anticancer Research. 2009;29(11):4759-64. PMID 20032432.

10. Taal B, Peterse H, Boot H. Clinical presentation, endoscopic features and treatment of gastric metastases from breast carcinoma. Cancer. 2000;89(11):2214-21. https://doi.org/10.1002/1097-0142(20001201)89:11<2214::AID-CNCR9>3.0.CO;2-D

11. Jones GE, Strauss DC, Forshaw MJ, Deere H, Mahedeva U, Mason RC, et al. Breast cancer metastasis to the stomach may mimic primary gastric cancer: report of two cases and review of literature. World Journal of Surgical Oncology. 2007;5:75. https://doi.org/10.1186/1477-7819-5-75

12. Wong YM, Jagmohan P, Goh YG, Putti TC, Ow SGW, Thian YL, et al. Infiltrative pattern of metastatic invasive lobular breast carcinoma in the abdomen: a pictorial review. Insights Imaging. 2021;12(1):181. https://doi.org/10.1186/s13244-021-01120-4

13. Xu L, Liang S, Yan N, Zhang L, Gu H, Fei X, et al. Metastatic gastric cancer from breast carcinoma: a report of 78 cases. Oncology Letters. 2017;14:4069-77. https://doi.org/10.3892/ol.2017.6703

This is an open access article distributed under the terms of the Creative Commons license.