REVIEW ARTICLE
https://doi.org/10.29289/259453942021056

Free nipple graft: current indications and applications of a centenary breast surgery technique – an integrative review

Clécio Ênio Murta de Lucena[1], Rafael Araujo Ponce de Leon[2]*, Ana Carla Araújo Paiva[2], Carla Sobreira da Nóbrega[2], Isabela Ferreira Bahia[2]

ABSTRACT

Introduction: Free nipple graft is a mammaplasty technique first described about 100 years ago. Its indication, restricted to reduction mammoplasty earlier, has been expanding into areas in mastology intervention, such as transgender and oncological surgery. **Aim:** The aim of this study was to evaluate the efficacy and outcomes of the technique. **Methods:** Electronic literature search was conducted, using PubMed and LILACS databases. The search strategy consisted of the keywords, MeSH terms, and free text words and variants for the free nipple graft and its application in reduction and mammaplasty, transgender, and oncoplastic surgery. **Results:** A total of 397 articles were found and, after inclusion and exclusion criteria, 15 were selected. Their outcomes have been shown, despite lack of standardized scores, as well as clinical trials to postulate better scientific evidence on its use and indications, that the technique, analyzed in over 1290 patients, achieved high safety rates and reproducibility. **Conclusion:** Aesthetics and patients satisfaction were found positive, as recommended by the authors in different studies discussed in this article.

KEYWORDS: free nipple graft; mammaplasty; transgender; breast neoplasms

INTRODUCTION

The surgical technique of free nipple graft (FNG), or areola autograft (Figures 1-3), was first described about 100 years ago by the Hungarian-American doctor named Max Thorek in 1922[1,2]. Its application was originally meant exclusively to reduction mammaplasty, but later expanded its role into areas of mastology intervention, such as oncoplastic surgery[3] and chest adjustment surgery in transgender males[4,5]. Despite the wide utilization and usefulness of FNG in mastology, this technique lacks reviews and secondary studies in literature that evaluate the efficiency and outcomes of its use. Thus, the importance of a single technique as FNG on interventional surgical treatment of multiple disorders related to breast such mammary hypertrophy, gender dysphoria, and even in potential life-threatening diseases, like cancer, is an emerging topic in mastology studies.

Symptomatic mammary hypertrophy is a medical condition that directly affects the physical and emotional health of the patients. Headache, cervical and back pain, as well as self-esteem problems are frequently related to this condition[6]. Randomized clinical trials (RCTs) have shown that conservative therapy is ineffective in improving symptoms and that reduction

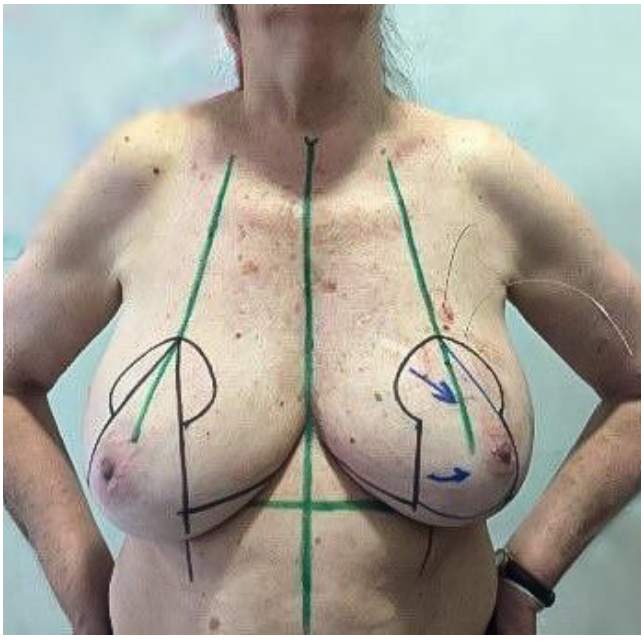

Figure 1. Preoperative marks that guide the surgical approach and incision sites. The upper blue arrow indicates the position where replacement of the nipple graft should be implanted.

[1]Universidade Federal de Minas Gerais, Instituto Orizonti, Breast Center – Belo Horizonte (MG), Brazil.
[2]Universidade Federal de Minas Gerais – Belo Horizonte (MG), Brazil.
***Corresponding author:** rfapleon@hotmail.com
Conflict of interests: nothing to declare. **Funding:** none.
Received on: 11/03/2021. **Accepted on:** 02/21/2022.



Figure 2. The nipple areolar complex is de-epithelized, as a graft, that must be preserved in a saline solution while breast parenchyma is resected.



Figure 3. Reinsertion of the areola graft in the breast resected with sutures.

mammaplasty surgery remains the only intervention with the ability to reduce the patients'[7] physical and psychological complaints, with approximately 129,000 surgeries being performed in 2017 with this purpose, according to the National Association of Plastic Surgeons[8].

In this scenario, the technique first described by Thorek[1,2] in 1922, i.e., FNG, represented a mark in mammoplasty reduction at the time, due to its ability to maintain the nipple areolar complex (NAC), compared to underexplored by prior used techniques, such glandular and skin excision described by Frenchmen Morestin in 1908[1]. Despite its aesthetic functional limitations, related to insufficient breast projection and total loss of sensibility and lactation function of the nipple[1,2,9-11], FNG remains the first choice technique in patients with gigantomastia weighing 1000 g and ptotic breasts[11]. Moreover, modifications of the original technique are providing new alternatives for indicating the use of FNG[9-11].

In the past few years, sociocultural changes and a better understanding on gender dysphoria have been increasing the demand for masculinizing transgender procedures of the chest wall, in which mastectomy is one of the most efficient approaches on improving psychological outcomes of dissociation between body gender and biological sex experienced by these patients[5]. Literature reviews and comparative analysis on different surgical techniques have shown that double incision-free nipple graft (DIFNG), an adaptation of Thorek's technique, is the first choice in selected patients, as it promotes aesthetic satisfying outcomes and optimization of the relocation of the NAC, as well as lower rates of reoperations and anatomic limitations when compared to other chest wall masculinizing transgender techniques[4,5].

Breast cancer is the most prevalent malignant neoplasia in women. According to the World Health Organizations (WHO), approximately 2.2 million women were diagnosed with the disease in 2020[12]. The progress in understanding and treatment of the disease made interventions possible, which, in addition to being curative, also provides a better aesthetic functional outcome in patients who undergo mastectomies and breast reconstruction. In this scenario, FNG has been indicated as an alternative option in the maintenance of the NAC in women who would be initially excluded from reconstructive surgery using the nipple-sparing mastectomy (NSM) due to anatomical limitations of the breasts, such as ptotic breasts and gigantomastia. Therefore, women who would be excluded from NSM can undergo FNG surgery and, in a two or a single surgical time, undergo NSM, maintaining the NAC and elevating their psychological and self-esteem.

OBJECTIVES

This literature review seeks to provide an updated synthesis of knowledge about the FNG technique and its outcomes related to aesthetics satisfaction, functionality, and safety profile, as well as to analyze its incorporation and applicability in several intervention areas involved in mastology and plastic surgery.

METHODS

A structured electronic literature search was conducted, using PubMed and LILACS databases. The search strategy consisted of the keywords, MeSH terms, and free text words and word variants for the FNG and its application in reduction mammaplasty, transgender, and oncoplastic surgery. In PubMed databases, a search was conducted using the keywords, such as "breast neoplasms" OR "transgender" OR "mammaplasty" AND "free nipple graft." The Mesh terms in PubMed were "Breast Neoplasms" [Mesh]) OR ("Transgender Persons" [Mesh]) OR ("Mammaplasty" [Mesh])) AND free nipple graft. In LILACS databases, the keywords were "breast neoplasms" OR "transgender" OR "mammaplasty" AND "nipple."

The PICO question was formulated: breast neoplasms, transgender, and mammaplasty as the problems in question; FNG as an intervention; other mammaries surgical techniques and noninterventional treatments as a control and aesthetics; and patients satisfaction, safety profile, and reproducibility as outcomes.

Date of publication was limited to the past 10 years. The following filter was applied: language (English). A hand search of bibliographies was conducted to identify any additional articles by two of the authors. All titles and abstracts were independently reviewed by two of the authors. All study types, such as RCTs, case-control, cohort, reviews, and case studies, were eligible for inclusion.

The different study designs and the heterogeneity of the outcomes reported in the studies precluded the possibility of pooling data across the studies. Therefore, a narrative synthesis was conducted.

RESULTS

A total of 397 articles were found (209 in PubMed and 188 in LILACS databases) and, after inclusion and exclusion criteria, 15 were selected according to PRISMA 2020 presentation in Figure 4. Results are summarized in Table 1.

From the selected articles, only four evaluated the traditional application of FNG in reduction mammaplasty, comparing it to other technique interventions and analyzing its current concepts and surgical complications[13-16]. A total of 824 patients and 1648 operated breasts were analyzed, with an average of 1250 g of resected parenchyma. The other six articles[17-22] refer to the applicability of FNG in oncoplastic surgery, in which a total of 123 patients and 238 mastectomies have been analyzed. Finally, five articles deal with FNG utility in masculinizing transgender surgery[23-27], with 343 patients and 721 mastectomies analyzed.

Roje et al.[13] performed a retrospective study involving 59 patients, with a mean age of 48.5 years old (p=0.271) and 1050 g of parenchyma removed (p=0.009). The study compared the inferior pedicle, inverted T-scar, and FNG techniques based on aesthetic and functional outcomes and, therefore, determined a more suitable technique for each patient. The authors emphasizes the importance of FNG technique for reduction mammaplasty, since it provides a possibility of parenchyma resection in patients at high surgical risk, such as smokers (OR=61.92; p=0.008). Moreover, it is able to be performed in reduced surgical time, aspect directly related to lower complication rates (OR=1.05; 95%CI 1.01–1.1; p=0.019). When compared to other techniques, it has been elected as first choice in patients with macromastia, those with ptotic breast, or those who are at high surgical risk.

Robert et al.[14], in a retrospective analysis of 715 mammaplasty reduction surgeries, with a mean age of 38 years old, 27 kg/m^2 of body mass index (BMI) and suprasternal notch-nipple distance of 31.6 cm, when comparing the FNG technique to the superior pedicle technique, found that the FNG had lower overall surgical complication rates (OR=1.57; 95%CI 0.73–3.38 vs. OR=2.64; 95%CI 1.54–4.61). In addition, it allows a greater parenchyma resection (average 1100 g vs. 501 g; p<0.0001). However, authors narrow the FNG technique use only in patients with ptosis or macromasty[14,15] due to functional impairments involved in its application, such as total loss of NAC sensibility, nipple hypopigmentation, and insufficient breast projection, being preferable to use techniques with greater vascular safety profile in nonselected patients, since FNG has higher rates of areolar necrosis when compared to the inferior pedicle technique (61 vs. 4.7%; p<0.0045).

One of the major problems historically related to FNG is a partial loss of mammary projection [9-11,14]. This aspect was approached by Karsidag et al.[15] who reported a better projection and aesthetic outcome through a modification of the original Thorek´s technique, using a dermoglandular flap associated with a suture of pectoralis major within the parenchyma. It provided a satisfactory breast contour and projection in all 24 patients with severe macromastia over 1000 g and breast ptosis, with a mean distant suprasternal notch nipple of 48.5 cm. The outcomes were analyzed comparing preoperative and postoperative photographs, as well as a questionnaire filled out by the surgeon that considered patients' satisfaction and lasting breast projection for 1 year. Finally, the authors recommend the adoption of their modified technique for surgeons experienced in performing original FNG. Moreover, the authors highlight, as an advantage, the fact that the technique can be easily performed and exchanged intraoperatively, If an occlusion of nipple perfusion, such as ischemia, is identified, it can be converted into a pedicle technique, which may offer a higher vascular safety profile.

Fırat et al.,[16] in their prospective study, in which 26 patients who underwent free nipple graft vertical mammaplasty using the Graf dermoglandular flap mastopexy as a novel autoprosthesis procedure with an average follow-up period of 22 months were evaluated for a conical breast shape with better projection and upper pole fullness after surgery. The average weight of removed breast tissue was 1634 g for the right breast and 1630 g for the left breast. The mean sternal notch-nipple distance was 37.1 cm,

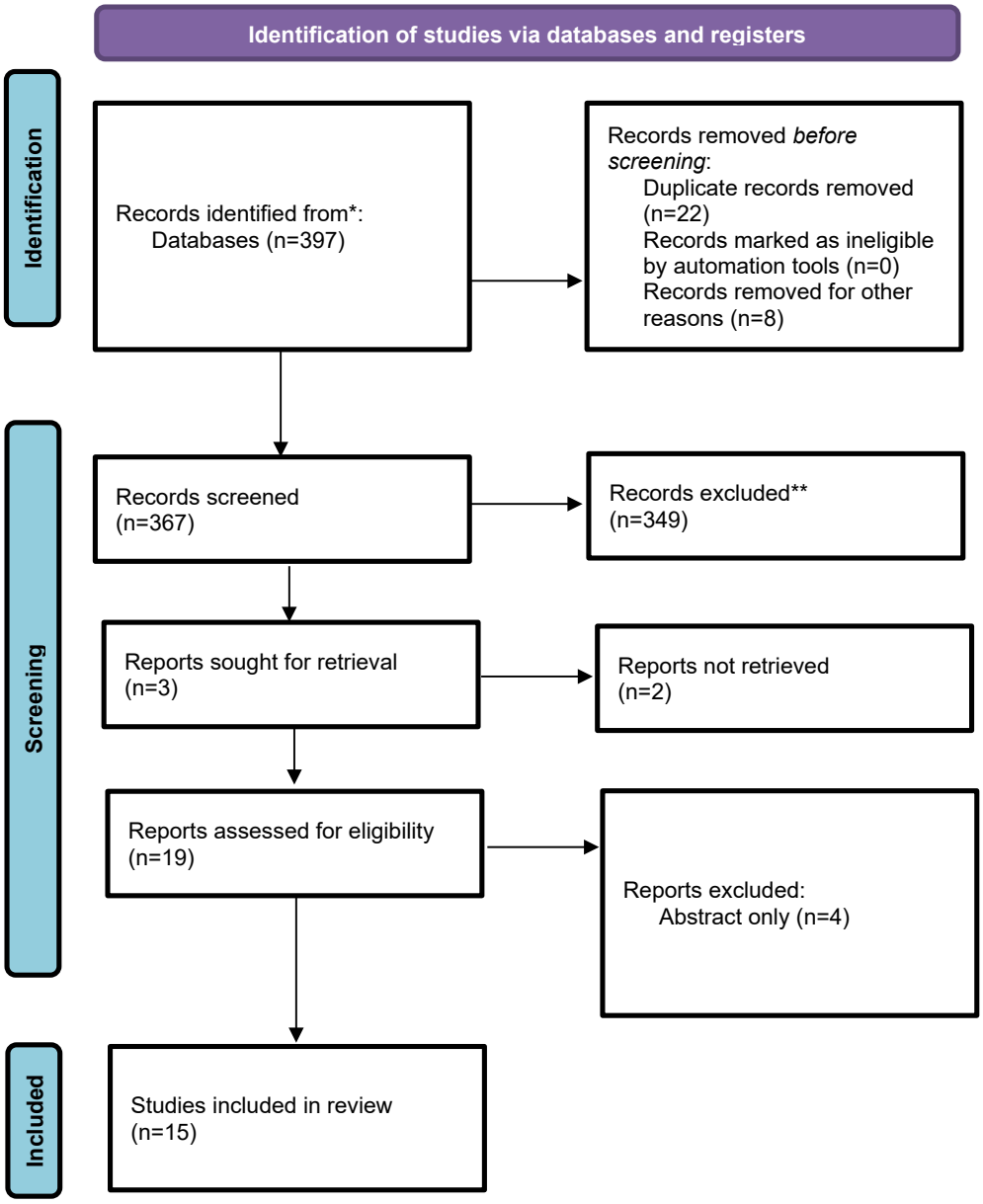

Figure 4. Prisma flow diagram.

and the mean nipple-submammary fold distance was 20.7 cm. The authors concluded that novel autoprosthesis technique yields a conical breast shape with better projection and upper pole fullness, thereby providing a better long-term aesthetic outcome than previous procedures for treating patients with gigantomastia. The examinations performed 2 years postoperatively clearly show that the autoprosthesis increased breast projection and preserved breast shape in the long term. This technique is easy to perform and highly suitable for patients with gigantomastia.

The role of FNG in reduction mammaplasty for decades prospected new possibilities for its use. Kijima et al.[17] explored FNG as a reconstructive plastic modified technique, associated with partial mastectomy in breast cancer conservative treatment. The authors reported a case of a 65-year-old woman who suffered from a bilateral ductal carcinoma in situ, who would have a compromised reconstruction surgery aesthetic result, in case of being submitted to the conventional pedicled technique, due to ptotic breasts. In this case, doctors opted to perform a partial bilateral mastectomy followed by a breast amputation with FNG. The modified technique was able to achieve a satisfactory oncological safety outcome in all quadrant areas, considering that the removal of the NAC from its original site

Table 1. List of articles according to title, author, year of issue, procedures, number of patients, and results.

Title/theme	Author and year of issue	Procedures and number of patients	Results
Mammaplasty			
Current trends in breast reduction	Roje et al.[13]	Retrospective cohort analysis of 59 patients who suffered from symptomatic macromasty and underwent surgical intervention from 1995–2011.	The free nipple graft technique is preferred for macromasty in smoker patients at high surgical risk.
Complications of breast reduction about 715 breasts	Robert et al.[14]	Retrospective cohort analysis of 715 patients who underwent a reduction mammaplasty in multiple techniques.	The free nipple graft has lower general rates of complications compared to the pedicle technique. Yet, its functional and aesthetic limitations as well as its high risk of mammillary necrosis restrict its use to severe macromasty and ptosis.
Reduction mammaplasty using the free-nipple-graft vertical technique for severe breast hypertrophy: improved outcomes with the superior dermaglandular flap	Karsidag et al.[15]	Prospective cohort study of 24 patients who suffered from severe mammary hypertrophy operated from 2003–2009.	The modified free nipple graft technique has shown to be effective in maintaining breast projection in all patients within the study. Experienced surgeons in superior pedicle technique used in reduction mammaplasty can adopt the suggested technique free nipple graft associated with superior dermoglandular flap.
An autoprosthesis technique for better breast projection in free nipple graft reduction mammaplasty	Fırat et al.[16]	26 patients who underwent free nipple graft vertical mammaplasty combined with the Graf dermoglandular flap mastopexy procedure were evaluated for a conical breast shape with better projection and upper pole fullness after surgery.	The novel autoprosthesis technique described yields a conical breast shape with better projection and upper pole fullness, thereby providing a better long-term aesthetic outcome than previous procedures for treating patients with gigantomastia.
Oncoplastic surgery			
Oncoplastic surgery combining partial mastectomy with breast reconstruction using a free nipple-areola graft for ductal carcinoma in situ in a ptotic breast: report of a case.	Kijima et al.[17]	Case report of a 65-year-old patient with ductal carcinoma in situ associated with ptotic breast.	The free nipple graft technique can be performed with reduced surgical time when compared to the inferior pedicle technique and it is indicated for the treatment of carcinoma in situ in women with ptotic breast.
Free nipple grafting: an alternative for patients ineligible for nipple-sparing mastectomy?	Doren et al.[18]	Retrospective cohort analysis of 15 ineligible patients for nipple-sparing mastectomy who underwent free nipple graft free nipple graft in order to maintain the nipple areolar complex.	In case of anatomical incompatible criteria for nipple-sparing mastectomy, free nipple graft is a viable option. The graft success rates were 95%, and the complication rates including loss of projection and hypopigmentation were, respectively, 19% and 27%.
Free nipple grafting and nipple sharing in autologous breast reconstruction after mastectomy.	Egozi et al.[19]	A prospective analysis of 13 patients who underwent free nipple graft after mastectomy with autologous reconstruction.	The free nipple graft technique achieved high aesthetic satisfaction rates: 4.6 out of 5 in Nahabedian score, as well as low rates of complications. Only 1 out of 13 grafts did not succeed and 24% of the nipples did not maintain pigmentation.
Nipple-sparing mastectomy and ptosis: using a free nipple graft with tissue expander reconstruction	Ghidei et al.[20]	Retrospective cohort of 14 patients submitted to free nipple graft in an oncological center.	The proposed free nipple graft intervention allowed women with breast ptosis to undergo NSM with preservation of the nipple areolar complex. Graft-taking was 100%. Yet, complications such as mammillary necrosis, hypopigmentation, and loss of sensibility were observed, respectively, in 7, 14, and 100% of the cases.
Revisiting the free nipple graft: an opportunity for nipple-sparing mastectomy in women with breast ptosis.	Chidester et al.[21]	A series of case reports on three women with breast cancer who were ineligible for nipple-sparing mastectomy and underwent a free nipple graft procedure.	Women who were previously excluded for nipple-sparing mastectomy were able to maintain nipple areolar complex integrity with free nipple graft with no oncological harm.

Continue...

Table 1. Continuation.

Title/theme	Author and year of issue	Procedures and number of patients	Results
One-stage breast reconstruction using the inferior dermal flap, implant, and free nipple graft	King et al.[22]	A reconstruction using free nipple graft was performed following a wise pattern skin incision in 16 patients and 19 breasts. A prospective database was kept from it.	The inferior dermal flap with implant and free nipple graft is an excellent single-stage reconstruction option. This method offers a potentially safe, reliable, and aesthetically acceptable outcome for women with larger, ptotic breasts.
Transgender surgery			
Long-term changes in free nipple graft morphology and patient-reported outcomes in gender-affirming mastectomies	Timmerman et al.[23]	Data from two prospective cohorts were collected: 67 transgender men after a mastectomy with free nipple grafts and 150 cisgender men (reference sample). Both groups were compared to establish the long-term changes in nipple-sparing mastectomy morphology and compare these to cisgender male nipple-sparing mastectomy outcomes.	Satisfaction for size, shape, and flatness decreased significantly after postoperative day 30 in transgender men compared to cisgender men.
Our experience in mastectomy for transgenders female to male – A 90 cases cohort study	Wolf et al.[24]	Retrospective cohort of 180 mastectomies performed in 20 years in transgender men.	The two main techniques performed with the best indicators of satisfaction and complications were nipple-sparing mastectomy flap and nipple-sparing mastectomy graft.
The nipple split sharing vs. conventional nipple graft technique in chest wall masculinization surgery: can we improve patient satisfaction and aesthetic outcomes?	Bustos et al.[25]	Retrospective cohort analysis of 68 transgender patients who underwent free nipple graft or nipple split intervention.	The nipple split and the conventional free nipple graft techniques did not show statistically significant complication rates. Yet, the nipple split had higher satisfaction rates compared to conventional free nipple graft technique
Modified nipple flap with free areolar graft for component nipple-areola complex construction: outcomes with a novel technique for chest wall reconstruction in transgender men	Frey et al.[26]	Retrospective cohort analysis including 50 transgender patients who underwent free areolar graft technique.	The techniques allow nipple-sparing mastectomy reconstruction in an effective and safe way. General complication rates were 10%.
A review of 101 consecutive subcutaneous mastectomies and male chest contouring using the concentric circular and free nipple graft techniques in female-to-male transgender patients	Knox et al.[27]	Retrospective analysis of 101 transgender patients who underwent either free nipple graft or concentric circular surgical techniques.	The concentric circular technique showed better aesthetic results in a score proposed by the study. However, the free nipple graft technique showed lower rates of complications.

reduces recidivation, in addition to a shortened surgical time when compared to other techniques used in oncological surgeries such as the pedicle technique[13,18]. Besides, FNG provides a better outcome regarding breast symmetry, due to the possibility of positioning nipple intraoperatively according to surgeon metrics. Therefore, authors highly recommend FNG application in the conservative oncological treatment of women with ptotic breasts in early stages of cancer.

The use of FNG in oncological mastology continues to be explored by Doren et al.[18] and Egozi et al.[19]. The nipple-sparing mastectomy (NSM) is a consolidated technique to achieve aesthetic results in mammary reconstruction[5,18,19]. However, in some cases, due to anatomical limitations and exposition factors, there is a contraindication to surgery using NSM, being left to perform a prior reconstruction followed by NSM in two surgical times. In retrospective cohort study by Doren et al.[18], 15 patients who were previously excluded from NSM due to previous areolar incision (n=2), breast parenchyma weighing >700 g (n=2), ptosis (n=1), radiation therapy (n=5), and patient's desire for autologous reconstruction (n=5) underwent a modified technique NSM associated with FNG in a single surgical time. A total of 26 areolar grafts were analyzed with a mean age of 47 years old, and 518.5 g of breast parenchyma. The graft viability was 95%, and the complication rate for loss of projection and hypopigmentation were, respectively, 19% and 27%. Doren et al.[18] concluded that FNG is a viable option for patients who do not fit classic indications and, therefore, is initially excluded from nipple-sparing surgery. The complication rates of FNG in oncoplastic surgery are similar

to those of reduction mammaplasty surgeries performed with the technique. Moreover, it spares patients from a doubled surgical time and its complications. Egozi et al.[19] retrospectively studied 7 patients in whom 13 FNG surgeries were performed. Initially, those patients were not excluded from NSM, as they were at high risk of mammillary necrosis. The mean age of the patients was 39.7 years old, and the mean BMI was 30.1 kg/m^2. All of them suffered from ptotic breasts (Regnault's grade II or III), and the average of parenchyma resected was 953 g. Finally, the authors reported a taking of 12 (93%) out of 13 grafts, with only 3 (24%) had hypopigmentation, and regarding a rate scale, based on Nahabedian patient satisfaction score, the FNG intervention achieved 4.6 out of 5. Therefore, FNG use is highly recommended by the authors owing to its high aesthetic satisfaction and low complication rates, potentially sparing patients from mammillary necrosis[18].

Ghiedei et al.[20] in their retrospective cohort study verified, as a primary outcome, the graft viability and postoperative complications in women who suffered from ptotic breasts. They underwent skin-sparing mastectomy, with oncoplastic purpose, followed by FNG in a single surgical time, aiming to maintain the integrity of NAC. In the retrospective study of 14 patients analyzed from 2014 to 2017, 10 suffered from invasive breast carcinoma and 4 underwent prophylactic mastectomy due to high-risk familiar history of breast cancer. The authors found that the use of FNG is able to maintain NAC integrity after mastectomy in women with ptosis, as well as achieved high rates of aesthetic satisfaction and free resection margins in an oncological perspective[18,19]. However, complications such as partial nipple necrosis, hypopigmentation, and loss of NAC sensibility were found, respectively, in 7, 14, and 100% of the patients observed in the study, reinforcing the need for a captious analysis on the indication and guidance of FNG due to complications which may impact the patient's self-esteem and quality of life.

The FNG intervention in breast oncology continues to be explored in the literature in the cases report by Childester et al.[21], in which a series of cases of three different women suffering from breast ptosis and carcinoma in situ underwent five NSMs, followed by FNG in a single surgical time. Analysis found that 1 (20%) out of 5 areola grafts was not successful, though it did not require postoperative debridement. The authors concluded that FNG was able to maintain NAC and free oncological margin [18-21] when undergoing FNG and skin-sparing mastectomy in a single surgical time.

King et al.[22] conducted a prospective study on 16 patients with breast cancer who underwent reconstruction surgery, using an inferior dermal flap associated with free nipple graft in a one-stage procedure and analyzed oncological safety and postoperative complications. Patient average age was 54 years, and average operative time was 165 min. There were no immediate complications requiring reoperation. All retroareolar biopsies were benign and no locoregional recurrences have occurred. Two nipples had partial necrosis of the lower pole but healed with conservative treatment. No patients required any subsequent procedures to their reconstructed breast. Although authors reinforce this type of procedure is proper for only a minority of patients who are suitable for immediate reconstruction, such as those who have a large ptotic breast and who have a low likelihood of disease involving the nipple, they concluded that FNG associated with dermal flap is a safe method of implant-based reconstruction, giving an excellent cosmetic result in a single procedure.

Society has experienced a paradigm shift concerning gender and sexuality in the past few years. This context expanded the areas of intervention in mastology and plastic surgery. The demand for transgender mammaplasty surgery has been rising in recent years, and FNG mastectomy is highlighted as one of the first choice techniques for chest wall masculinizing surgery in these patients [4,5].

Timmerman et al.[23] performed an observational, cross-sectional study, with data collected from two prospective cohorts transgender men (n=57) after a mastectomy with free nipple grafts and cisgender men (n=150) as a reference sample. Demographics and 3D images were collected for both groups. NAC measurements were performed on the 3D images at four time points (i.e., 7, 30, 90, and 365 days postoperative) in transgender men and once in cisgender men. NAC width and height in trans men changed from 21.5±2.7 to 23.8±3.9 mm (p<0.001) and 16.2±2.5 to 14.7±3.0 mm (p=0.01) within a year, respectively. The mean NAC width and height in cisgender men were 28.1±5 and 20.7±4 mm, being significantly larger than that in transgender men. Satisfaction for size, shape, and flatness decreased significantly after postoperative day 30 (p=<0.05) in transgender men. Therefore, authors conclude morphology and satisfaction with the NACs in transgender men significantly decreased over time. They enforce that understanding and incorporating these differences into preoperative counseling and surgical planning might help increase patient satisfaction in a long-term status and not only in an immediate postoperative analysis.

In retrospective cohort of 90 patients and 180 mastectomies by Wolf et al.[24], two techniques NAC pedicle (41.1%) and NAC graft (41.1%), which is a modification of the original FNG technique, were the most used surgical procedures in transgender patients in the series of procedures performed by a single surgeon. A mean age of 22.4 years old and 467 g of resected breast parenchyma were analyzed, and the authors found that, although high satisfaction and low complication rates were found in total mastectomies, it is necessary to establish a clinical-surgical classification based on breast weight and symmetry, as well as clinical trials to define which technique is more suitable for transgender patients.

Bustos et al.[25] compared intraoperative and postoperative outcomes of two techniques, either based on FNG, used in chest wall transgender surgery, the DIFNG and the nipple split technique

performed in a total of 34 transgender patients, with a mean age of 24 years old and BMI of 32.2 kg/m^2, retrospectively analyzed from 2017 to 2019. Both techniques did not have statistical difference concerning intraoperative and postoperative complication rates; however, the nipple split technique achieved a higher satisfaction rate according to patients (90.7 vs. 58.1%, p<0.05) calculated by a Likert scale questionnaire. Thus, the authors concluded that the nipple split FNG is able to achieve good aesthetic results with low complication rates and a high security profile and that it should be recommended as a first choice in transgender mastectomies instead of DIFNG.

Frey et al.[26] analyzed symmetry and plasticity of NAC, as a primary outcome, in 50 transgender patients who underwent DIFNG from March 2015 to October 2016. The mean age of patients was 30.6 years old, and the mean weight of resected breast parenchyma was 627.8 g. The authors concluded DIFNG has a satisfactory safety profile. General complication rates including seromas, cellulitis, and hematomas were about 10%, and specific aesthetic-related complications that needed reintervention to adjust size or symmetry of NAC were about 8%. Therefore, the authors recommend the adoption of the technique in transgender mastectomies due to its high aesthetic and success rates.

Knox et al.[27] reviewed 101 masculinizing mastectomies surgeries comparing two consolidated techniques in transgender patients: FNG and circular concentric. The authors found FNG had lower complication rates (12.7% vs. 37%; p<0.01). In addition, they found circular concentric technique achieved better aesthetic outcomes in the score proposed by the authors based on scar healing and breast shape ranging from 1 to 5 (circular concentric score 3.39 vs. 2.62 FNG; p<0.01). Therefore, the authors reduce the recommendation for the FNG technique in patients with BMI>27 kg/m^2 and distance nipple inframammary fold longer than 7 cm and patients who might be at a high surgical risk. Furthermore, the authors reinforce the need for standardized evaluation scores and clinical trials to define, with a higher evidence-based conduct, the most suitable technique for transgenders masculinizing mastectomies.

DISCUSSION

A variety of surgical applications has been described for the free nipple graft technique. The data from the present literature and research have shown promising results that may provide plastic and mastology surgeons with an evidence-based incentive to adopt the FNG technique in its broad spectrum of intervention.

Moreover, the possibility to modify Thorek's original technique[14,15] was explored in this study as a viable way to improve aesthetic problems in reduction mammaplasty, such as insufficient breast projection. This possibility was already discussed in literature back to the 90s by Romano et al.[9] and Abramson et al.[10]

Some restrictions to the FNG use, described in the past decades, which limited its use to strict cases of reduction mammaplasty with over 1 kg per breast to be resected, or sternal notch-nipple distance longer than 35 cm, were already questioned by Colen et al.[11] The authors suggest that FNG may achieve equal or better aesthetic and functional outcomes compared to traditional reduction mammaplasty techniques, such as inferior pedicle, not only in its classic indications for gigantomastia or breast weighing >1 kg but also in cases of preeminent ptosis, inverted nipple, and fatty breasts. Transgender individuals who underwent surgery using FNG had average breast parenchyma resection of 490 g in the studies[24-26]. That gives support to Colen et al.[11] questioning on limitations to FNG use in parenchyma weighing 1000 g to be resected and suggests misconception of those prior restrictions related to FNG indications.

As a subtype of free skin graft, FNG had already been studied in some references back to the 2000s when it was seen that inclusion criteria for breast conservative surgery continued to evolve, including lower quadrants mastectomy and large breasts. Spear et al.[28]. reviewed on 11 women with macromastia who underwent lumpectomy followed by mammaplasty reduction, using FNG in 8 out of 22. The authors have already determined the importance of this gathered oncoplastic procedure, in that the potential for disfigurement after breast conservative treatment would increase, especially in some risk patients, such as women with macromastia. Authors found similar results compared to some in this article[17,22] when it comes to recognize the importance of a coordinated oncoplastic program and the benefits in boosting self-esteem in those patients, but Spear et al.[28] also reinforced the need for better define and improve algorithms for selecting women who might benefit from this type of the procedure, since patients with macromastia are at higher surgical risk when compared to most patients. In the articles[17-22] found in this revision, none of them have proposed a standardized algorithm neither for macromastia nor for ptotic breasts in oncoplastic treatment.

Some limitations to this revision were also found. Except Robert et al.[14], none of the studies analyzed a broad population with a standardized statistic score of outcomes, such as risk ratio and aesthetic results when it comes to compare various techniques used in reduction mammaplasty, oncoplastic, and transgender surgery. In this manner, a reduced sample limits a significant statistical analysis. Besides, a historical problem concerning difficulties in performing clinical trials related to surgical interventions[29] was also present in the literature concerning FNG as no RCT was found in the databases, which may reduce methodological and evidence strength of this study.

Another fact that must be considered is the lasting of the aesthetics results, especially in transgender surgeries. Timmerman et al.[23] were the only authors who approached a lasting satisfaction over 1 year in contrast of the other articles on transgender surgery[24-27]. This aspect could be more explored since nonlasting results may have impact on self-esteem and morbidity problems in those patients[5].

Despite these considerations regarding methodological and articles limitations, it is important to emphasize a broad applicability of FNG technique and its limited dissemination and

use in breast surgery. Notwithstanding inconveniences related to FNG technique, such total loss of nipple sensibility, areolar depigmentation, and flattening of the papilla over time, it is also necessary to reinforce the low rate of loss of graft as well as aesthetic result similar or better to those found using conventional mammaplasty techniques. Moreover, in cases of oncological surgeries, in which maintaining NAC would not be possible after mastectomy in ptotic or bulky breasts, FNG may be used for the maintenance of the NAC or correction of malposition of it after conservative or radical mastectomies[17,18].

CONCLUSIONS

The literature data analysis provides a broad view of possibilities in breast surgery using the FNG technique and its safety profile. This study represents a potential impact on both experienced and learner surgeons when providing the most complete and updated information about a technique with a large spectrum of intervention in mammaplasty, oncological, and transgender surgery. Furthermore, we reinforce the need for adequate interventional trials and standardized aesthetic functional scores in order to define with a better level of evidence the usefulness of FNG.

AUTHORS' CONTRIBUTION

RP: Conceptualization, Methodology, Formal Analysis, Investigation, Writing – original draft. AA: Conceptualization, Data curation, Writing – original draft, Writing – review & editing. CN: Conceptualization, Data curation, Writing – original draft, Writing – review & editing. CE: Supervision, Project Administration, Formal Analysis, Writing – review & editing.

REFERENCES

1. Wamalwa AO, Stasch T, Nangole FW, Khainga SO. Surgical anatomy of reduction mammaplasty: a historical perspective and current concepts. S Afr J Surg. 2017;55(1):22-28. PMID: 28876554.
2. Mattioli WM, Penazzi Júnior SA, Melo DSF. Use of the back-folded dermaglandular inferior pedicle in mammary amputation: improving results. Rev Bras Cir Plást. 2017;32(3):339-45. https://doi.org/10.5935/2177-1235.2017RBCP0057
3. Kim EK, Cho JM, Lee JW. Skin-sparing mastectomy and immediate nipple graft for large, ptotic breast. J Breast Cancer. 2019;22(4):641-6. https://doi.org/10.4048/jbc.2019.22.e52
4. Etemad SA, Furuyama WM, Winocour JS. Double Incision Mastectomy with Free Nipple Graft for Masculinizing Chest Wall Surgery. Plast Reconstr Surg Glob Open. 2020;8(11):e3184. https://doi.org/10.1097/GOX.0000000000003189
5. Wilson SC, Morrison SD, Anzai L, Massie JP, Poudrier G, Motosko CC, et al. Masculinizing Top Surgery: A Systematic Review of Techniques and Outcomes. Ann Plast Surg. 2018;80(6):679-83. https://doi.org/10.1097/SAP.0000000000001354
6. Santos GR, Araújo DC, Vasconcelos C, Chagas RA, Lopes GG, Setton L, et al. Impacto da mamoplastia estética na autoestima de mulheres de uma capital nordestina. Rev Bras Cir Plást. 2019;34(1):58-64. https://doi.org/10.5935/2177-1235.2019RBCP0009
7. Saariniemi KM, Keranen UH, Salminen-Peltola PK, Kuokkanen HO. Reduction mammaplasty is effective treatment according to two quality of life instruments. A prospective randomised clinical trial. J Plast Reconstr Aesthet Surg. 2008;61(12):1472-8. https://doi.org/10.1016/j.bjps.2007.09.024
8. American Society of Plastic Surgeons. Plastic surgery statistics report 2017. ASPS National clearinghouse of plastic surgery procedural statistics. 2018 [cited on Mar 01, 2022]. Available from: https://www.plasticsurgery.org/documents/News/Statistics/2017/plastic-surgery-statistics-full-report-2017.pdf.
9. Romano JJ, Francel TJ, Hoopes JE. Free nipple graft reduction mammoplasty. Ann Plast Surg. 1992;28(3):271-6. https://doi.org/10.1097/00000637-199203000-00012
10. Abramson DL. Increasing projection in patients undergoing free nipple graft reduction mammoplasty. Aesthetic Plast Surg. 1999;23(4):282-4. https://doi.org/10.1007/s002669900284
11. Colen SR. Breast reduction with use of the free nipple graft technique. Aesthet Surg J. 2001;21(3):261-71. https://doi.org/10.1067/maj.2001.116439
12. World Health Organization. Breast cancer. 2021 [cited on May 25, 2021]. Available from: www.who.int/news-room/fact-sheets/detail/breast-cancer
13. Roje Z, Roje Z, Milosević M, Varvodić J, Mance M. Current trends in breast reduction. Coll Antropol. 2012;36(2):657-68. PMID: 22856260
14. Robert G, Duhamel A, Alet JM, Pelissier P, Pinsolle V. Complications des réductions mammaires à propos de 715 seins [Complications of breast reduction about 715 breasts]. Ann Chir Plast Esthet. 2014;59(2):97-102. https://doi.org/10.1016/j.anplas.2014.01.003
15. Karsidag S, Akcal A, Karsidag T, Yesiloglu N, Yesilada AK, Ugurlu K. Reduction mammaplasty using the free-nipple-graft vertical technique for severe breast hypertrophy: improved outcomes with the superior dermaglandular flap. Aesthetic

Plast Surg. 2011;35(2):254-61. https://doi.org/10.1007/s00266-010-9592-9

16. Fırat C, Gurlek A, Erbatur S, Aytekin AH. An autoprosthesis technique for better breast projection in free nipple graft reduction mammaplasty. Aesthetic Plast Surg. 2012;36(6):1340-6. https://doi.org/10.1007/s00266-012-9984-0

17. Kijima Y, Yoshinaka H, Hirata M, Mizoguchi T, Ishigami S, Arima H, et al. Oncoplastic surgery combining partial mastectomy with breast reconstruction using a free nipple-areola graft for ductal carcinoma in situ in a ptotic breast: report of a case. Surg Today. 2011;41(3):390-5. https://doi.org/10.1007/s00595-010-4294-0

18. Doren EL, Kuykendall LE, Lopez JJ, Laronga C, Smith PD. Free nipple grafting: an alternative for patients ineligible for nipple-sparing mastectomy? Ann Plast Surg. 2014;72(6):S112-5. https://doi.org/10.1097/SAP.0000000000000077

19. Egozi D, Allwies TM, Fishel R, Jacobi E, Lemberger M. Free nipple grafting and nipple sharing in autologous breast reconstruction after mastectomy. Plast Reconstr Surg Glob Open. 2020;8(9):e3138. https://doi.org/10.1097/GOX.0000000000003138

20. Ghidei L, Bansil HA, Stuckey A, Pandya S, Edmonson D, Michaud P, et al. Nipple-sparing mastectomy and ptosis: using a free nipple graft with tissue expander reconstruction. Plast Reconstr Surg Glob Open. 2020;8(2):e2623. https://doi.org/10.1097/GOX.0000000000002623

21. Chidester JR, Ray AO, Lum SS, Miles DC. Revisiting the free nipple graft: an opportunity for nipple sparing mastectomy in women with breast ptosis. Ann Surg Oncol. 2013;20(10):3350. https://doi.org/10.1245/s10434-013-3122-3

22. King IC, Harvey JR, Bhaskar P. One-stage breast reconstruction using the inferior dermal flap, implant, and free nipple graft. Aesthetic Plast Surg. 2014;38(2):358-64. https://doi.org/10.1007/s00266-014-0276-8

23. Timmermans FW, Elfering L, Smit JM, van de Grift TC, Bouman MB, Mullender MG. Long-term changes in free nipple graft morphology and patient-reported outcomes in gender-affirming mastectomies. Aesthetic Plast Surg. 2022. https://doi.org/10.1007/s00266-021-02666-w

24. Wolf Y, Kwartin S. [Our experience in mastectomy for transgenders female to male – a 90 cases cohort study]. Harefuah. 2020;159(8):595-9. PMID: 32852161

25. Bustos SS, Forte AJ, Ciudad P, Manrique OJ. The nipple split sharing vs. conventional nipple graft technique in chest wall masculinization surgery: can we improve patient satisfaction and aesthetic outcomes? Aesthetic Plast Surg. 2020;44(5):1478-86. https://doi.org/10.1007/s00266-020-01803-1

26. Frey JD, Yu JZ, Poudrier G, Motosko CC, Saia WV, Wilson SC, et al. Modified Nipple Flap with Free Areolar Graft for Component Nipple-Areola Complex Construction: Outcomes with a Novel Technique for Chest Wall Reconstruction in Transgender Men. Plast Reconstr Surg. 2018;142(2):331-6. https://doi.org/10.1097/PRS.0000000000004551

27. Knox ADC, Ho AL, Leung L, Hynes S, Tashakkor AY, Park YS, et al. A review of 101 consecutive subcutaneous mastectomies and male chest contouring using the concentric circular and free nipple graft techniques in female-to-male transgender patients. Plast Reconstr Surg. 2017;139(6):1260e-72e. https://doi.org/10.1097/PRS.0000000000003388

28. McKissock PK. Reduction mammaplasty with a vertical dermal flap. Plast Reconstr Surg. 1972;49(3):245-52. https://doi.org/10.1097/00006534-197203000-00001

29. Spear SL, Pelletiere CV, Wolfe AJ, Tsangaris TN, Pennanen MF. Experience with reduction mammaplasty combined with breast conservation therapy in the treatment of breast cancer. Plast Reconstr Surg. 2003;111(3):1102-9. https://doi.org/10.1097/01.PRS.0000046491.87997.40

30. McCulloch P, Taylor I, Sasako M, Lovett B, Griffin D. Randomised trials in surgery: problems and possible solutions. BMJ. 2002;324(7351):1448-51. https://doi.org/10.1136/bmj.324.7351.1448

This is an open access article distributed under the terms of the Creative Commons license.