CASE REPORT
https://doi.org/10.29289/2594539420210053

Changing the molecular profile of primary and metastatic breast cancer identified by Foundation One: case report

Izabella Fernandes Viana Montechi[1]*, Patrícia Werlang Schorn[2], Amanda Damazio Cabral[1], Juliana Sinezio Santos[1], Alessandra Vanessa Leite e Silva[2]

ABSTRACT

Objective: To describe a case report of a patient who presented with bilateral breast cancer with progression to metastatic disease, in which immunohistochemical profile of the primary and metastatic tumor was divergent. **Methods:** This was a study with a descriptive narrative and reflective design, of the case report type, based on secondary data, with information and images obtained from the electronic medical records of the MVSoul system used in the oncology center of a private hospital in the Federal District in Brazil. Data collection was derived from the analysis of data and images of the electronic medical record. **Case report:** A patient presented with bilateral metastatic breast cancer, and the primary and metastatic breast tumors showed a difference in immunohistochemical profile. Accordingly, we highlight the rarity of the case, the need for biopsies of metastatic lesions because of the molecular heterogeneity of breast cancer and possible discrepancy between the primary tumor and metastases. Spreading knowledge about diagnostic tests and personalized treatment according to tumor molecular characteristics is also essential, especially when the patient does not have a satisfactory therapeutic response, as in the reported case, since the patient had metastases with different molecular profiles confirmed only by of tumor DNA sequencing.

KEYWORDS: breast neoplasms; metastasis; biopsy; cytogenetic analysis.

INTRODUCTION

Breast cancer is the most common type of malignant neoplasm in Brazilian women, with an annual incidence of 66,280 cases (29.7%), and it was the main cause of cancer death In 2020, where 18,068 (16.4%) deaths from breast cancer were registered[1]. According to international guidelines, breast cancer is uncommon in women under 40 years of age, representing less than 7% of all diagnosed cases[2]. Even rarer is the involvement of a second contralateral primary breast cancer, corresponding to a mean annual incidence rate of 0.5%[3,4]. Over the years, scientific discoveries have shown that this neoplasm has significant molecular heterogeneity, and an immunohistochemical evaluation of the disease is essential to characterize the status of the progesterone (PR) and estrogen (ER) receptors, HER2 expression and Ki67 cell proliferation index[2,5]. According to these data, breast carcinoma is classified as luminal A, luminal B, HER2-positive or triple-negative (TN).

Breast cancer has extensive molecular heterogeneity, so it cannot be seen as a single entity, since patients with different molecular subtypes have differences in survival and different therapeutic possibilities[6]. Luminal tumors are those enriched by hormone receptors (ER and/or PR) and include special types, such as tubular, cribriform, lobular and mucinous carcinomas. On the basis of Ki67, a cut-off point of 14% was established to distinguish luminal A and B tumors. By definition, luminal A tuors are those that are hormone receptor positive, HER2-negative and Ki67-positive up to 14%, while luminal B ones are those that are hormone receptor-positive and HER2-positive or -negative and have a Ki67 index greater than 14%[7]. Those tumors that do not express the HER2 protein or hormone receptors are called triple-negative tumors, and they are more aggressive[8-10].

Generally, the characteristics of metastatic breast cancer, like other types of cancer, are similar to those of the initial disease. However, more and more studies demonstrate a

[1]Hospital Santa Lucia Sul, Clinical Oncology – Brasília (DF), Brazil.
[2]Hospital Santa Lucia Sul, Oncologist – Brasília (DF), Brazil.
***Corresponding author:** izamontechi@hotmail.com
Conflict of interests: nothing to declare. **Funding:** none.
Received on: 10/29/2021. **Accepted on:** 12/31/2021.

divergent molecular profile between the initial breast tumor and the recurrent or[11] metastatic one, which can be attributed to the cellular heterogeneity of the cancer, as well as the selective expression of receptors by cell clones at the end of the initial treatment[11]. All this makes it often necessary to biopsy the new lesion, especially when the patient does not have a satisfactory therapeutic response[12].

A study carried out with a large cohort of patients in the Stockholm region (Sweden) estimated that, at relapse, 32%, 41% and 15% of patients showed a change in ER, PR and HER2 status, respectively[11,13,14]. It also highlights that women with initially ER-positive tumors who transformed into ER-negative had a significantly increased risk of death by 48% compared to stable ER patients[11].

Another multicenter cohort study, PriMet, retrospectively evaluated 635 breast cancer patients between 1980 and 2010. Discrepancies in hormone receptors and HER2 status between primary tumor and recurrent disease were observed in 18.7% and 21.6% of cases, respectively[15,16]. Regarding hormone receptor presence, positivity in the primary tumor and its absence in the relapsed disease were more frequent, while for the expression of HER2, the opposite was observed[16].

Cancer treatment is undergoing an essential shift with the use of molecularly targeted drugs for selected subsets of patients with various tumor types, resulting in more effective and safer treatment. Diagnostic tests that show individual genomic alterations are essential for the successful application of personalized therapy[17]. Parallel (or "next generation") DNA sequencing, successfully applied in the research environment to elucidate the complexity of the cancer genome, is becoming an attractive clinical diagnostic technology because it can accurately detect most genomic changes in all therapeutically relevant cancer genes in a single trial[18].

Given the complexity of this disease, it is necessary to promote effective interventions, and it is essential to better understand the relevant molecular characteristics and their influence on prognosis. Likewise, it is essential to know the therapeutic possibilities to achieve the best possible prognosis and longer disease-free survival for the patient.

Therefore, the present work is justified by the importance of disseminating knowledge about a cancer whose prognosis and treatment depend on its molecular characteristics.

METHODS

This was a study with a descriptive design of a narrative and reflective character, of the case report type, based on secondary data, with information and images obtained from the electronic medical record of the MVSoul system used in the oncology center of a private hospital in the District Federal. The information was collected through the analysis of data and images from the electronic medical record.

CASE REPORT

A 39-year-old patient came to the outpatient clinic in 2004 with a complaint of a palpable lump in the right breast. Breast ultrasound revealed two breast nodules, which were biopsied: 1. Invasive ductal carcinoma (IDC), grade II, 0.7x0.5 cm in the lower left quadrant. 2. IDC, grade II, 0.3x0.2 cm in the upper left quadrant. Clinical status T1N0M0. Immunohistochemistry showed ER+, PR++, HER2++, Ki67++, FISH negative. Patient underwent left quadrantectomy with negative sentinel lymph node (SL) investigation, followed by radiotherapy and use of tamoxifen for five years.

She was under clinical follow-up when, in 2009, at the age of 44, after ending the use of tamoxifen, she had recurrence of the skin neoplasm. We opted for a right radical mastectomy with axillary dissection and a left prophylactic mastectomy with negative SL. Anatomopathology (AP) of the right breast surgical specimen showed IDC, grade II, 3x2x1.5 cm, skin infiltration, with four compromised lymph nodes of 15 resected, pT4pN2 M0, ER+, PR+, HER2-negative and Ki67 10%, while the AP prophylactic mastectomy of the left breast found a second primary tumor: IDC, grade I, 1.4 cm, luminal B, LS negative. Chemotherapy was started with AC-T (docetaxel) regimen, external radiotherapy in the breast plastron and use of adjuvant anastrozole for five years (until 2014), because at that time the patient was postmenopausal.

In May 2017, three years after anastrozole was discontinued, follow-up examinations showed suspected disease progression to the bones, lungs, and mediastinum. Bone biopsy (sternum) showed AP compatible with metastatic adenocarcinoma, immunohistochemistry: ER 80%, PR negative, Ki67 50%, HER2 negative. At this point, she was on faslodex for five cycles, showing clinical worsening and rapid progression of the disease to the liver. She then opted for the Foundation One genetic test, which indicated no detectable genetic alterations. There was a change of treatment to chemotherapy with paclitaxel+bevacizumab for six cycles, when there was new disease progression to the bones during treatment.

The regimen was changed to eribulin for four cycles, with a good initial response, but followed by a new one for progression, this time for the lungs and mediastinum. With the arrival of CDK4/6 inhibitors, palbociclib with letrozole was chosen for four cycles, however, with further worsening of the disease in bones, lungs and liver.

In view of the extensive history and lack of therapeutic response, a new bone biopsy (iliac) was performed, where AP confirmed IDC with ER 60%, PR negative and HER2 negative. Material was sent again to Foundation One, and the result was different from the previous ones, including HER2 amplification.

Once HER2 amplification was verified, the patient started using trastuzumab emtansine every 21 days, combined with letrozole and denosumab, with excellent clinical, metabolic and radiological complete response for a year and a half. There was then focal progression of the disease in the central nervous system, where she underwent radiosurgery and then started a double block with Herceptin and Perjeta. To date, the patient uses double HER2 blockade, with clinical stability and no evidence of disease (Figure 1).

DISCUSSION

Breast cancer is the most common type of malignant neoplasm in Brazilian women, with an annual incidence of 66,280 cases (29.7%), and the main cause of cancer death. In 2020, 18,068 (16.4%) deaths from breast cancer were identified[1]. According to international guidelines, breast cancer is uncommon in women under 40 years of age, accounting for less than 7% of all diagnosed cases[2]. The involvement of a second contralateral primary breast cancer is even rarer, corresponding to an average annual incidence rate of 0.5%[3].

Research carried out by the Cooperative Breast Cancer Group in Denmark evaluated 68,466 patients with breast cancer between 1978 and 2012, of which only 4% had a second contralateral primary tumor, and the prognosis was considerably worse when compared to unilateral disease[4]. There are many risk factors for breast cancer; however, for contralateral disease, these factors are not well established[5].

Over the years, scientific discoveries have also shown that breast tumors have remarkable molecular heterogeneity, and an immunohistochemical evaluation of the disease is essential to characterize PR and ER status, HER2 expression and Ki67[2] index.

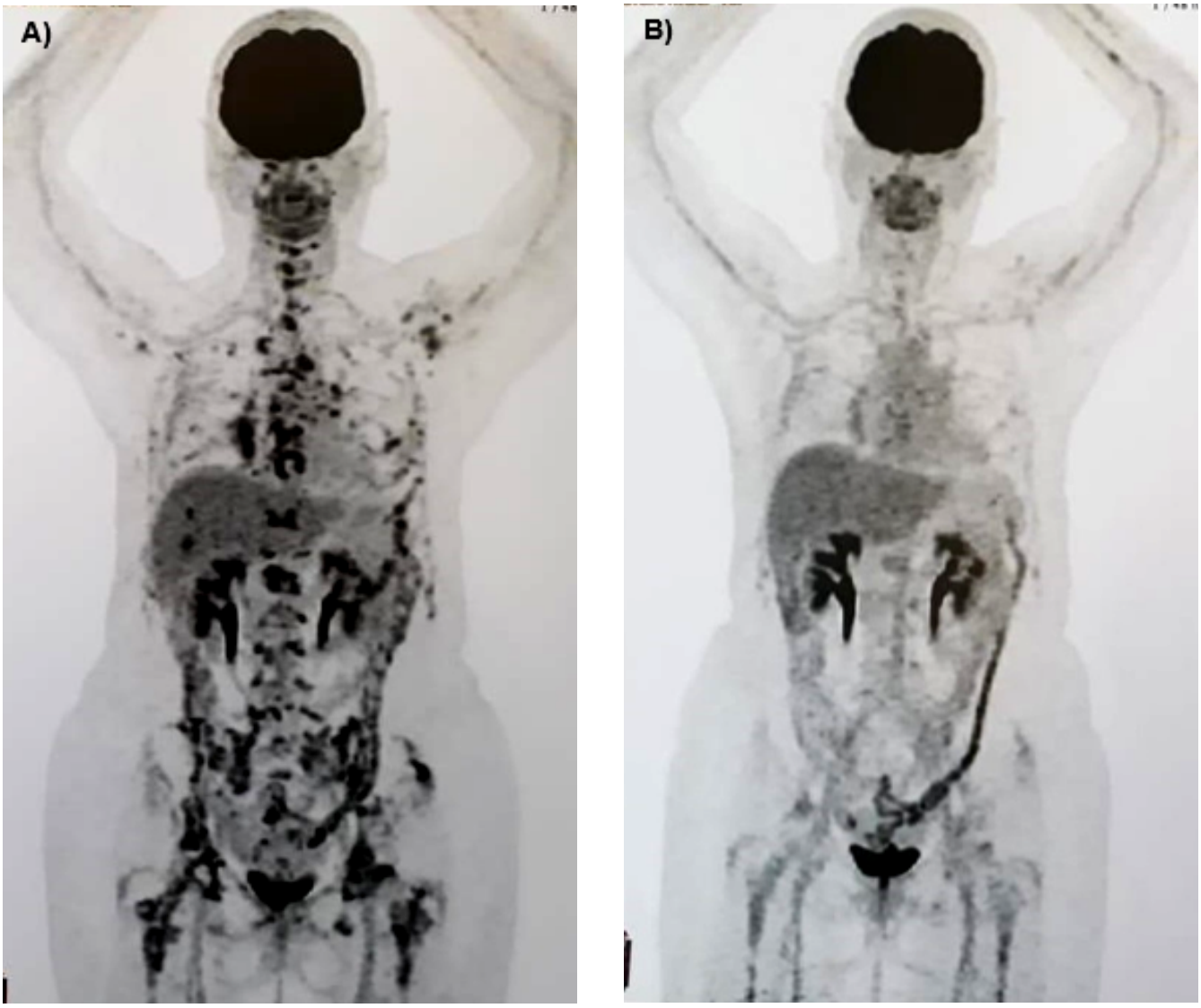

Figure 1. A) PETCT of the patient before starting treatment with trastuzumabe entansina combined with letrozol and denosumabe; B) PETCT of the patient at the end of treatment with trastuzumabe entansina combined with letrozol and denosumabe.

And it is according to each molecular subtype that survival rate is determined and therapeutic possibilities defined[6].

Luminal tumors are those enriched by hormone receptors (ER and/or PR) and include special types such as tubular, cribriform, lobular and mucinous carcinomas. On the basis of the Ki67 level, a cohort point of 14% was established to distinguish luminal A and B tumors. By definition, luminal A tumors are those that are hormone receptor-positive, HER2-negative and Ki67-positive up to 14%, while luminal B ones are those that are hormone receptor-positive and HER2-positive or -negative with Ki67 index greater than 14%[7]. Those that do not express the HER2 protein and do not have hormone receptors are called triple-negative (TN) tumors and are more aggressive[8-10].

Luminal A tumors are those with the lowest metastatic potential, while luminal B and HER2-positive tumors have as main metastatic sites the central nervous system, liver and lung, as well as bones. TN tumors metastasize to any location[11].

The British Columbia Cancer Agency followed patients with early-stage breast cancer diagnosed between 1986 and 1992 and found high rates of brain metastases in the HER2 overexpressed (28.7%) and TN (22%) groups[15].

A retrospective cohort performed at Seoul National Hospital (South Korea) analyzed 1,432 patients with stage I to III breast cancer who underwent surgery and systemic treatment when indicated, with a mean follow-up of 53 months. The five-year breast cancer-free interval, according to subtype, was 93.9% for luminal A, 94.2% for luminal B with HER2 positive, 91.4% for luminal B with HER2 negative, 83.1% for HER2 positive and 81.9% for TN. The overall five-year survival rate was 98.3%, 95.8%, 98%, 90.8% and 89.9% for luminal A, luminal B with HER2 negative, luminal B with HER2 positive, HER2 positive and TN, respectively[12].

An Asian study evaluated recurrence rates according to molecular subtype and found: 5% for luminal A, 7.8% for luminal B with HER2 negative, 6.6% for luminal B with HER2 positive, 13.1% for HER2 positive and 16.7% for TN[13]. Kennecke and coworkers (2010) followed 313 women with breast cancer for 93 months and observed that the site of distant recurrence varied according to molecular subtype: in luminal A and B, the most common pattern of recurrence was in the bones, while for HER2-positive and TN, visceral involvement was more common[14].

The molecular characteristics of metastatic breast cancer, like other types of cancer, are often similar to those of the initial disease. However, more and more studies have shown a divergent molecular profile between the initial tumor and the recurrent or metastatic one. This can be attributed to the cellular heterogeneity of cancer and the selective expression of receptors by cell clones after the initial treatment[11]. Because of this, biopsy of the new lesion is often necessary, especially when the patient does not have a satisfactory therapeutic response. A large cohort study of patients in the Stockholm region estimated that, at relapse, 32%, 41% and 15% of patients showed a change in ER, PR and HER2 status, respectively.

It is noteworthy that women with initially ER-positive tumors who transformed into ER-negative had an increased risk of death by about 48% when compared with stable ER patients[11]. PriMet, a multicenter cohort study, evaluated 635 breast cancer patients between 1980 and 2010. Discrepancies in hormone receptors and HER2 expression between primary tumor and recurrent disease were observed in 18.7% and 21.6 % of cases, respectively. The positivity in the primary tumor and its absence in the recurrent disease were more frequent for hormone receptors, while for HER2 expression, the opposite was observed[16].

The treatment of breast cancer is undergoing an essential change with the use of molecular-targeted drugs, based on a better understanding of this molecular heterogeneity and resulting in a more effective and safer treatment. Diagnostic tests that show individual genomic alterations are essential for the successful application of personalized therapy[17] based on tumor DNA sequencing. This clinical diagnostic technology has been extremely attractive because it can accurately detect most genomic changes in all therapeutically relevant tumor genes[18]. Speeding up the selection of effective drugs based on the identification of gene mutations in tumor DNA becomes essential, since patients with metastatic breast cancer carry a history of several previously received therapeutic lines, as in this case, resulting in reduced tumor cell sensitivity to the drugs used[19].

CONCLUSIONS

A patient presented with tumors in both breasts, metastatic and with different immunohistochemical profile between the primary tumor and the metastasis. Thus, the rarity of the case, the need for rebiopsy of metastatic or recurrent lesions due to the molecular heterogeneity of breast cancer and possible discrepancy between the primary and recurrent tumors are highlighted. Spreading knowledge about diagnostic tests and personalized treatment, considering their molecular characteristics, is also essential, especially when the patient does not have a satisfactory therapeutic response, as in the case reported, since the patient had lesions with different molecular profiles confirmed only with tumor DNA sequencing.

AUTHORS' CONTRIBUTION

IFVM: Data curation, Methodology, Writing – original draft, Writing – review & editing. PWS: Methodology, Writing – original draft. ADC: Methodology, Writing – original draft. JSS: Data curation, Writing – original draft. AVLS: Data curation, Writing – original draft.

REFERENCES

1. Brazil. Ministério da Saúde. Instituto Nacional de Câncer José Alencar Gomes da Silva. Estatísticas de Câncer [internet]. Rio de Janeiro: Inca; 2021. [cited on October 10, 2021]. Available at: https://www.inca.gov.br/numeros-de-cancer
2. Franzoi MA, Rosa DD, Zaffaroni F, Werutsky G, Simon S, Bines J, et al. Advanced stage at diagnosis and worse clinicopathologic features in young women with breast cancer in Brazil: a subanalysis of the AMAZONA III study (GBECAM 0115). J Glob Oncol. 2019;5:1-10. https://doi.org/10.1200/JGO.19.00263
3. Spronk I, Schellevis FG, Burgers JS, Bock GH, Korevaar JC. Incidence of isolated local breast cancer recurrence and contralateral breast cancer: a systematic review. Breast. 2018;39:70-9. https://doi.org/10.1016/j.breast.2018.03.011
4. Langballe R, Frederiksen K, Jensen MB, Andersson M, Cronin-Fenton D, Ejlertsen B, et al. Mortality after contralateral breast cancer in Denmark. Breast Cancer Res Treat. 2018;171(2):489-99. https://doi.org/10.1007/s10549-018-4846-3
5. Rasmussen CB, Kjær SK, Ejlertsen B, Andersson M, Jensen MB, Christensen J, et al. Incidence of metachronous contralateral breast cancer in Denmark 1978-2009. Int J Epidemiol. 2014;43(6):1855-64. https://doi.org/10.1093/ije/dyu202
6. Provenzano E, Ulaner GA, Chin SF. Molecular classification of breast cancer. PET Clin. 2018;13(3):325-38. https://doi.org/10.1016/j.cpet.2018.02.004
7. Cheang MC, Chia SK, Voduc D, Gao D, Leung S, Snider J, et al. Ki67 index, HER2 status, and prognosis of patients with luminal B breast cancer. J Natl Cancer Inst. 2009;101(10):736-50. https://doi.org/10.1093/jnci/djp082
8. Bitencourt AGV, Lima ENP, Chojniak R, Marques EF, Souza JA, Luciana Graziano L, et al. Correlação entre resultado do PET/CT e achados histológicos e imuno-histoquímicos em carcinomas mamários. Radiol Bras. 2014;47(2):67-73. https://doi.org/10.1590/S0100-39842014000200006
9. Caldarella A, Buzzoni C, Crocetti E, Bianchi S, Vezzosi V, Apicella P, et al. Invasive breast cancer: a significant correlation between histological types and molecular subgroups. J Cancer Res Clin Oncol. 2013;139(4):617-23. https://doi.org/10.1007/s00432-012-1365-1
10. Corben AD. Pathology of invasive breast disease. Surg Clin North Am. 2013;93(2):363-92. https://doi.org/10.1016/j.suc.2013.01.003
11. Lindström LS, Karlsson E, Wilking UM, Johansson U, Hartman J, Lidbrink EK, et al. Clinically used breast cancer markers such as estrogen receptor, progesterone receptor, and human epidermal growth factor receptor 2 are unstable throughout tumor progression. J Clin Oncol. 2012;30(21):2601-8. https://doi.org/10.1200/JCO.2011.37.2482
12. Lee Y, Kang E, Lee AS, Baek H, Kim EK, Park SY, et al. Outcomes and recurrence patterns according to breast cancer subtypes in Korean women. Breast Cancer Res Treat. 2015;151(1):183-90. https://doi.org/10.1007/s10549-015-3390-7
13. Shim HJ, Kim SH, Kang BJ, Choi BG, Kim HS, Cha ES, et al. Breast cancer recurrence according to molecular subtype. Asian Pac J Cancer Prev. 2014;15(14):5539-44. https://doi.org/10.7314/apjcp.2014.15.14.5539
14. van Uden DJP, van Maaren MC, Strobbe LJA, Bult P, van der Hoeven JJ, Siesling S, et al. Metastatic behavior and overall survival according to breast cancer subtypes in stage IV inflammatory breast cancer. Breast Cancer Res. 2019;21(1):113. https://doi.org/10.1186/s13058-019-1201-5
15. Kennecke H, Yerushalmi R, Woods R, Cheang MC, Voduc D, Speers CH, et al. Metastatic behavior of breast cancer subtypes. J Clin Oncol. 2010;28(20):3271-7. https://doi.org/10.1200/JCO.2009.25.9820
16. Kolberg-Liedtke C, Wuerstlein R, Gluz O, Heitz F, Freudenberger M, Bensmann E, et al. Phenotype Discordance between Primary Tumor and Metastasis Impacts Metastasis Site and Outcome: Results of WSG-DETECT-PriMet. Breast Care (Basel). 2021;16(5):475-83. https://doi.org/10.1159/000512416
17. Frampton GM, Fichtenholtz A, Otto GA, Wang K, Downing SR, He J, et al. Development and validation of a clinical cancer genomic profiling test based on massively parallel DNA sequencing. Nat Biotechnol. 2013;31(11):1023-31. https://doi.org/10.1038/nbt.2696
18. Roychowdhury S, Iyer MK, Robinson DR, Lonigro RJ, Wu YM, Cao X, et al. Personalized oncology through integrative high-throughput sequencing: a pilot study. Sci Transl Med. 2011;3(111):111ra121. https://doi.org/10.1126/scitranslmed.3003161
19. National Comprehensive Cancer Network. NCCN Guidelines. Fort Washington: National Comprehensive Cancer Network; 2021 [cited on October 10, 2021]. Available at: https://www.nccn.org/guidelines/guidelines-detail?category=1&id=1419.

This is an open access article distributed under the terms of the Creative Commons license.