REVIEW ARTICLE
https://doi.org/10.29289/2594539420210051

Integrative review on breast cancer screening in the transgender population: what do we know?

Maria Julia Gregorio Calas[1], Rebeca Fernandes de Azevedo Dantas[1]*, Carolina Bantim Ciscotto[1], Bruna Galper[1], Ingrid Meira Lopes de Carvalho[1], Juliana Moreira Guerra[1]

ABSTRACT

The lack of formal breast cancer screening guidelines for the transgender population and the unpreparedness of health professionals to provide adequate health care to this population are described in the literature. The objective of this integrative review was to present the proposals for breast cancer screening in the transgender population, based on the literature, being searched in the Medline, PubMed, SciELO, and Lilacs databases. The articles that addressed breast cancer screening in the female and/or male transgender population were selected, in addition to the associated studies with the use of hormone therapy and breast cancer in transgender people, using the terms such as "transgender people," "early cancer diagnosis," and "breast." Of the 38 articles selected, 24 address recommendations for breast cancer screening in the female and/or male transgender population. There is limited population-based information on mammography screening in transgender people, which ultimately affects the analysis of cancer incidence in this population. The literature supports screening in the male transgender profile (similar to the female cisgender). In transgender females, recommendations are implemented based on expert's opinions, such as mammographic screening after 5 years of hormone use. More studies on this subject are needed.

KEYWORDS: transgender persons; early detection of cancer; breast.

INTRODUCTION

Breast cancer is recognized as the most common malignant disease in the female population, representing 13% of all cancer deaths in women worldwide[1-3].

Mammography is still the best method for breast cancer screening and has been proven to reduce mortality due to this type of cancer[1-3]. In Brazil, according to the Guidelines for the Early Detection of Breast Cancer, from the Ministry of Health, mammographic screening is recommended for women aged 50–69 years for a period of every 2 years. On the one hand the Brazilian Society of Mastology, the Brazilian College of Radiology, and the Brazilian Federation of Gynecology and Obstetrics recommend mammographic screening in women aged 40–74 years, annually, who are at usual risk[3].

Breast cancer affects not only women but also men in about 1% of cases[1,3,4]. As breast cancer in men is rare, there are no Brazilian guidelines for screening in men. Data from the American Society of Clinical Oncology suggest screening only in high-risk male patients, including the group of patients who have undergone breast cancer surgery and have proven genetic mutations[4].

However, it is noteworthy that despite the guidelines for breast cancer screening in cisgender women and in special situations in high-risk cisgender men, breast cancer can also affect transgender men and women[5-7].

Transgender is an umbrella term to describe a group of diverse individuals who cross or transcend culturally defined gender categories. This transgender population is composed of individuals who have gender incongruence with the biological sex assigned at birth and may be male, female, or non-binary (who are identified as neither male nor female sex, regardless of the biological sex at birth)[5,8,9].

Gender diversity is an area in a society marked by stigmas, causing failure in health care due to the lack of access and interest in the medical services for this population[5,8,9]. Briefly, the topic can be understood as having two main aspects:

1) the need to know the impact of hormonal treatments on the development of breast cancer; and
2) the need to educate these people as far as the early detection of this disease is concerned.

[1]Universidade Estácio de Sá – Rio de Janeiro (RJ), Brazil.
***Corresponding author:** rebecaf.dantas@gmail.com
Conflict of interests: nothing to declare. **Funding:** none.
Received on: 10/19/2021. **Accepted on:** 03/02/2022.

Thus, gender identification has peculiarities that deserve medical attention. This population lacks satisfactory studies and statistical significance regarding both the incidence of breast cancer and the possible ways of screening[8-11].

The main data recently published by Spizzirri et al.[5] point out the fact that Brazilian individuals with gender diversity represent approximately 2% of the country's adult population (almost 3 million people) and are homogeneously located throughout the country, reiterating the urgency of public health policies for these individuals in the five Brazilian subregions[5].

Given the relevance of the subject and the deficiency of research and studies on breast cancer screening in transgender people, the review aimed to present the main proposals for breast cancer screening in this population, described in the literature.

METHODS

This is an integrative review, in which the literature search was carried out in the search platforms PubMed, Medical Literature Analysis and Retrieval System Online (MEDLINE) databases, LILACS, and SciELO, using the following DECs and MeSH descriptors such as "transgender people," "early cancer diagnosis," and "breast."

The population included in this selection is female and/or male transgender people, in studies where the suggestion of different types of breast cancer screening was described (diagnostic intervention for breast cancer detection). As an outcome, it is expected that, in face of a standardized screening of this population, taking into account possible hormonal and surgical treatments, there will be an improvement in the quality of care provided to this population.

The extraction of data from the articles was carried out in a separate form, independently by two of the six authors. Duplicates (eight articles), abstracts, letters to journal editors, gray literature, and book chapters, as well as those that did not present in the title, abstract, or text the subject addressed in this review were excluded. It is worth mentioning that the studies repeated in the different databases were only excluded after being read in their entirety in order to avoid exclusion errors.

The main eligibility criteria articles were made available online in English, Portuguese, and Spanish, which addressed breast cancer screening in female and/or male transgender people. Articles that studied the encountered limitations by the transgender population in breast screening and studies that associated the use of hormone therapy and breast cancer in transgender people were also considered eligibility criteria.

For a better knowledge of important issues related to the transgender population, we complemented the review with the objective of identifying publications not captured by the electronic search, secondary references of articles, as well as additional searches of the literature on known and hypothesized cancer risk factors, the occurrence of cancer (incidence or prevalence) in a defined population of transgender persons, and the potential mechanisms by which exposure to these factors may affect cancer risk in this population.

Regarding the ethical issue of research by the National Health Council (Conselho Nacional de Saúde – CONEP), an evaluation was not necessary by an Ethical Research Committee (comitê de ética em pesquisa – CEP) according to Resolution No. 466/2012.

RESULTS

Of a total of the initially identified 76 articles, 38 were excluded. The flowchart about the selection of the articles is shown in Figure 1.

The articles that met all the selection criteria and made easier to answer the question of this review were selected (38 articles). Of this total, 24 were used to prepare the tables in this study. Of these 24 studies, 15 address the recommendation of screening in female and male transgender people, 8 articles address screening only in transgender males, and 1 article recommends screening only in transgender females.

The main results that were obtained by analyzing the articles from the bibliographic search and the proposed methodology are shown in Tables 1 and 2. The tables present the recommendations for breast cancer screening in the transgender population, which were divided into males[12-34] and females[12-16,18,20-23,27,28,31,33-35]. The tables also mention the references related to this review.

Regarding the proposed form of screening for the male transgender population, most articles suggest maintaining screening for transgender men with natal or residual breast tissue, in line with current guidelines for cisgender women[12-25]. Regarding the transgender female population, all studies indicate mammographic screening after 5 years of hormone (estrogen) use[12-16,18,20-22,27,28,31,33,35].

To finalize the screening proposals, Table 3 summarizes the publication of the joint national position of the Brazilian College of Radiology and Imaging Diagnosis, the Brazilian Society of Endocrinology and Metabology, and the Brazilian Society of Clinical Pathology, coordinated by Vieira and collaborators, national reference in breast cancer screening recommendations for the transgender population[6].

DISCUSSION

Transgender and nonbinary people have unique health care needs, which stems from gender-affirming hormone therapy and/or surgical interventions performed by this population[11,13,16,21,26,31]. The relationship between hormonal treatments in the sexual transition of female and male transgender people and the incidence of breast cancer is still discussed in the literature[13,16,26,31].

As the transgender community gains visibility and recognition, health disparities become more apparent[14,24,30]. Despite the efforts to become more inclusive, access to health care for this population is a challenge because it is a system built on a binary model. Another major challenge in caring for the

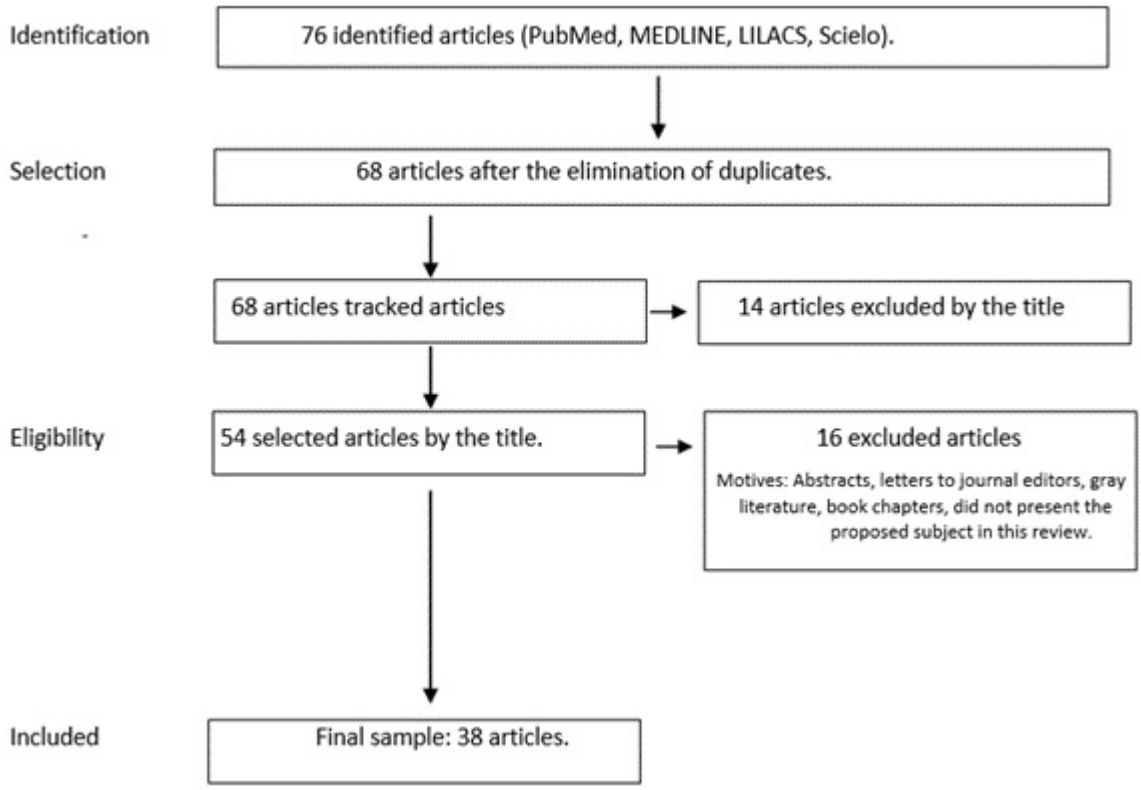

Figure 1. Flowchart of the selection of articles for the integrative review identification.

Table 1. Recommendations for breast cancer screening in the transgender male population found in the review.

Breast cancer screening recommendation in transgender males	Number (and respective reference) of articles found with this recommendation
Screening for transgender men with natal or residual breast tissue, according to current guidelines for cisgender women	15 articles[12-23,32-34]
Biennial mammography in transgender men who used hormone therapy aged 50–69 years	6 articles[24-29]
Annual MRI and mammography for transgender men aged 25–30 years. Consideration of prophylactic bilateral mastectomy for patients with BRCA2	1 article[30]
Annual mammogram for transgender men aged 40 years and above	1 article[31]

Table 2. Recommendations for breast cancer screening in the transgender female population found in the review.

Breast cancer screening recommendation in transgender females	Number (and respective reference) of articles found with this recommendation
Annual mammogram for transgender women with more than 5 years of hormone therapy, BMI>35 kg/m^2 or a family history of breast cancer Breast ultrasound and magnet resonance imaging or mammography with displacement mammography for those with breast prostheses	2 articles[13,34]
Mammography for transgender women undergoing hormone therapy for more than 5 years	3 articles[15,23,27]
Mammography every 2 years for transgender women aged 50 years and above who have been on hormone therapy for more than 5 years	5 articles[12,14,21,28,35]
Annual or biennial mammography for transgender women aged 50 years or above who are undergoing hormone therapy for more than 5 years and with additional risk factors: BMI>35 kg/m^2; family history of breast cancer	6 articles[16,18,20,22,31,33]

BMI: Body mass index.

Table 3. Recommendations for breast cancer screening in the male and female transgender population, according to the Joint Positioning of the Brazilian Society of Clinical Pathology, Brazilian Society of Endocrinology and Metabology, and Brazilian College of Radiology and Diagnostic Imaging.

Breast cancer screening recommendation in transgender males	Follows recommendations for cisgender women when bilateral mastectomy is not performed After bilateral mastectomy, mammographic screening is not recommended
Breast cancer screening recommendation in transgender females	Annual or biennial mammography, starting at age 50, in patients using hormone therapy for at least 5 years

transgender community is the scarcity of scientific and medical knowledge[16,28,30-33].

Most health professionals receive less or no training to provide clinically and culturally appropriate health care to these patient groups[7,14,34,35].

To date, no study is able to support a biological difference between transgender women and cisgender men, and between transgender men and cisgender women, since the incidence of breast cancer should be attributed to biological sex[27,29].

Transgender men or male transgender people

Hormone therapy for transition helps this population to modify some physical or visual characteristics to become more phenotypically like a man. In this scenario, with the use of testosterone, the suppression of the period of breast development (depending on the age at the beginning of hormone therapy), an increase in lean muscle mass, and a male-standard body development[13,16,20,36] are expected. Such characteristics, which are potentially affected, are noticed in the first month of testosterone use, as well as an increase in skin oiliness and libido around 3 months after the start of therapy (directly related to testosterone levels in the blood and inversely proportional to the luteinizing hormone levels)[13,16,20,36].

Concomitant with the external changes, histological evaluations of the endometrium of transgender men showed it to be atrophic and inactive, similar to the result observed in postmenopausal cisgender women without estrogen therapy. The menstrual period ceases approximately 2–6 months after initiation of testosterone hormone therapy. This process is faster when the therapy is used intramuscularly[13,16,20,36].

As in the female transgender population, the relationship between hormone therapy and the onset of breast cancer is not well established[14,20,36]. One of the postulated pathways is peripheral aromatization in the breast and adipose tissue, which converted dehydroepiandrosterone into estradiol and estrone, in postmenopausal women. Another hypothetical mechanism is the direct stimulation of androgen receptors. Normal breast cells as well as breast cancer cells express androgen receptors in large numbers[13,16]. Chotai and colleagues[20], in their study including 1,849 breast cancer patients, revealed that androgen receptor positivity was inversely related to clinical stage, histological tumor grade, and mitotic stage, suggesting an association of positivity between androgen receptors and less aggressive tumors[20].

Regarding the published studies of breast cancer in male transgender people, Blok and colleagues[29], with a sample of 1,229 men, identified four cases of invasive breast cancer, with a mean age of 46 years. Kiely[27], in a cohort of 5,135 transgender people using cross-hormonal therapy, described 10 case reports of breast cancer: 7 cases in transgender men, 2 in transgender women, and 1 in a nonbinary patient. From this perspective, there are few cases of breast cancer in transgender described, proving to be an uncommon disease, but not absent[24,28].

Gender-affirming mastectomy techniques vary significantly in relation to the amount of residual breast tissue, which has unknown implications for postoperative breast cancer incidence and the need for screening. Clinical examination remains the most commonly reported method of post-mastectomy malignancy detection[21,36]. For those who opted for a complete mastectomy, two authors recommend an annual clinical examination of the chest wall and armpits[21,27,28]. In the case of patients with a greater amount of residual breast tissue, they can be considered alternative imaging modalities, although the efficacy and cost-utility of these techniques have yet to be proven[21,27,28,36-38].

Preoperative patient counseling about the risk of breast cancer after masculinizing mastectomy, in addition to the unknown implications of residual breast tissue and long-term exposure to androgens, is essential[15,16,31,34].

There is still no established breast cancer screening guidelines for the transgender male population. However, some authors suggest screening based on the presence of breast tissue and risk factors[15,24,26,27,30,34,35].

According to the study by Pivo and colleagues[32], for transgender men, risk factors inherent to the female genotype should be considered, such as age, race, reproductive history, and family history of breast and ovarian cancers[13]. The study by Kiely[27] considered modifiable and non-modifiable factors for breast cancer risk, including family and personal history of breast and ovarian cancer, body mass index >35 kg/m^2 in menopausal women, early menarche, late menopause, and moderate or high alcohol consumption[27].

Based on the guidelines of the Brazilian Society of Clinical Pathology, the Brazilian Society of Endocrinology and Metabology, and the Brazilian College of Radiology and Diagnostic Imaging, breast cancer screening for transgender men is limited to the type of examination, age, and periodicity. Mammography is recommended biennially for transgender men who are not having

bilateral mastectomy and aged 50–69 years (as well as indicated for cisgender women at usual risk). For transgender men with bilateral mastectomy, screening is not indicated[6].

Transgender women or female transgender people

Transgender women undergo hormone therapy with estrogen in conjunction with antiandrogen drugs, such as spironolactone, to inhibit the action of testosterone. The effects of hormone therapy include breast growth, decreased facial hairiness, increased capillary volume, altered body fat distribution, and decreased testicle size. Approximately from 3 to 6 months, it is possible to visualize the beginning of these phenotypic changes; however, it is only 2 or 3 years of hormone therapy in which the maximum growth of the breasts is evidenced[26,31,33,34]. The degree of breast development appears to be independent of the type and dose of hormone treatment used. Once the maximum development of female characteristics is reached, it is necessary to reduce the offered hormonal dose[19,31].

After this process, the breast of the transgender woman has the same characteristics as the breast of a cisgender woman, with an exposure to develop benign tumors as well as malignant lesions. In addition, the potential increased risk of breast cancer with the use of exogenous hormones has not been completely elucidated, which makes it a challenge to assess the most appropriate screening recommendation in this population[22,31]. The potential risk goes beyond the increased risk of breast cancer in cisgender postmenopausal women undergoing estrogen hormone replacement therapy and is supported by the literature of case reports of breast cancer in transgender women[29,33,34].

Regarding the studies that present case reports of breast cancer cases in transgender females, Hartley and colleagues[31] described 22 transgender women with breast cancer after a literature review including 18 articles. The average age was 51.5 years, where 7 of them reported a first-degree relative with breast cancer and 1 had a confirmed mutation in the BRCA2 gene. Among the types of cancer, most were represented by adenocarcinomas (13 cases, 59.3%); BIA-ALCL (breast implant-associated anaplastic large-cell lymphoma) (3 cases, 13.6%); ductal carcinoma in situ (1 case, 4.5%); secretory carcinoma (1 case, 4.5%), malignant phyllode tumor (1 case, 4.5%); and Paget's carcinoma associated with invasive ductal carcinoma (1 case, 4.5%) and without histological classification (2 cases, 9.1%)[31].

Regarding the duration of hormone use, transgender women who presented with breast cancer used hormone therapy for an average of 18 years, with a predominance of luminal type tumors[12,22,29,33,34].

In the Dutch study by Blok and colleagues[29], in a group of 2,260 transgender women, 15 cases of invasive breast cancer were identified, with an average age of 52 years, which was comparatively lower than the average age (61 years) of involvement of Dutch cisgender women[29]. The incidence of breast cancer in these women was considered higher than the risk in Dutch cisgender men (0.4 expected cases), but below the expected benchmark for Dutch women (72 expected cases)[29].

The correlation of information obtained from the 15 articles selected in this review (Table 1) suggests mammographic screening in transgender women undergoing hormone therapy, after 5 years of use, although there is no consensus regarding its periodicity and age[12-16,18,20-23,27,28,31,33]. Screening mammography is not currently recommended for transgender women who are not using hormones, except in patients with other known risk factors, for example, those with Klinefelter syndrome[4,11].

According to the Brazilian societies, breast cancer screening in transgender women should be performed if they have been using hormone therapy for more than 5 years, with intervals of 1 or 2 years, starting at the age of 50 years. If hormone therapy is not used, screening is not indicated[6].

Some of these women opt for breast augmentation surgery with the use of breast implants. The surgery itself does not interfere with breast cancer risk, but it does affect the monitoring. In these cases, according to the studies by Schmidt and colleagues[21] and Hartley and colleagues[31], the use of ultrasound and magnetic resonance imaging of the breasts or mammography with the displacement of the breast implants is suggested for screening.

Awareness and education of these patients play an important role in shared decision-making, but more research is needed to define standards of care and breast cancer screening in this population[8,9,23].

CONCLUSIONS

Summarizing the main guidelines for breast cancer screening in transgender people, the literature describes the screening process for transgender men with natal or residual breast tissue, according to the current guidelines for cisgender women; and for the female transgender population, mammographic screening is indicated after 5 years of hormone use, but without consensus regarding the age of initiation and termination of this screening.

The severity and complexity of breast cancer, associated with the lack of robust data in the literature on the incidence and screening of this pathology in the group of transgender patients, indicate the need for further studies for a better understanding and applicability of the guidelines proposed in the literature.

AUTHORS' CONTRIBUTION

MJGC: Conceptualization, Data curation, Formal Analysis, Writing – original draft. RFAD: Conceptualization, Writing – review & editing. CBC: Conceptualization, Data curation, Writing – review & editing. BG: Visualization, Writing – original draft. IMLC: Methodology, Visualization. JMG: Writing – review & editing.

REFERENCES

1. Brazil. Ministério da Saúde. Rastreamento. Série A. Normas e Manuais Técnicos Cadernos de Atenção Primária, n. 29. Brasília: Ministério da Saúde, 2010.
2. Urban LABDU, Schaefer MB, Duarte DL, Santos RP, Maranhão NMA, Kefalas AL, et al. Recomendações do Colégio Brasileiro de Radiologia e Diagnóstico por Imagem, da Sociedade Brasileira de Mastologia e da Federação Brasileira das Associações de Ginecologia e Obstetrícia para rastreamento do câncer de mama por métodos de imagem. Radiol Bras. 2017;50(4):244-9. https://doi.org/10.1590/S0100-39842012000600009
3. Oliveira DAL. Políticas de saúde e diagnóstico precoce do câncer de mama no Brasil. Rev Enferm Digit Cuid Promoção Saúde. 2019;4(1):46-50. https://doi.org/10.5935/2446-5682.20190009
4. Hasset MJ, Somerfield MR, Baker ER, Cardoso F, Kansal KJ, Kwait DC, et. al. Management of male breast cancer: ASCO Guideline. J Clin Oncol. 2020;38(16):1849-63. https://doi.org/10.1200/JCO.19.03120
5. Spizzirri G, Eufrásio R, Lima MCP, Nunes HRCD, Kreukels BPC, Steensma TD, et al. Proportion of people identified as transgender and non-binary gender in Brazil. Sci Rep. 2021;11:2240. https://doi.org/10.1038/s41598-021-81411-4
6. Sociedade Brasileira de Endocrinologia e Metabologia (SBEM). Posicionamento Conjunto Medicina Diagnóstica inclusiva: cuidando de pacientes transgênero. Rio de Janeiro: Sociedade Brasileira de Patologia Clínica Medicina Laboratorial e Colégio Brasileiro de Radiologia e Diagnóstico por Imagem [Internet]. [cited on Jan 01, 2019]; 2019. Available from: https://www.endocrino.org.br/media/pdfs_documentos/posicionamento_trangenero_sbem_sbpcml_cbr.pdf
7. Pratt-Chapman ML, Ward AR. Provider recommendations are associated with cancer screening of transgender and gender-nonconforming people: a cross-sectional urban survey. Transgend Health. 2020;5(2):80-5. https://doi.org/10.1089/trgh.2019.0083
8. Puechl AM, Russel K, Gray BA. Care and cancer screening of the transgender population. J Womens Health 2019;28(6):761-8. https://doi.org/10.1089/jwh.2018.6945
9. Gibson AW, Radix AE, Maingi S, Patel S. Cancer care in lesbian, gay, bisexual, transgender and queer populations. Future Oncol. 2017;13(15):1333-44. https://doi.org/10.2217/fon-2017-0482
10. Bazzi AR, Whorms DS, King DS, Potter J. Adherence to mammography screening guidelines among transgender persons and sexual minority women. Am J Public Health. 2015;105(11):2356-8. https://doi.org/10.2105/AJPH.2015.302851
11. Phillips J, Fein-Zachary VJ, Mehta TS, Littlehale N, Venkataraman S, Slanetz PJ. Breast imaging in the transgender patient. AJR Am J Roentgenol. 2014;202:1149-56. https://doi.org/10.2214/AJR.13.10810
12. Charkhchi P, Schabath MB, Carlos RC. Modifiers of cancer screening prevention among sexual and gender minorities in the behavioral risk factor surveillance system. J Am Coll Radiol. 2019;16(4 Pt B):607-20. https://doi.org/10.1016/j.jacr.2019.02.042
13. Eneros AA, Zamorano SJ, Salazar RR, Lagos MAC. Terapia Hormonal en la Transición Masculino a Femenino (MTF) ó transexual femenino o régimen de feminización: parte II. Rev Soc Chil Obstet Ginecol Infant Adolesc. 2017;24(1):18-27.
14. Braun H, Nash R, Tangpricha V, Brockman J, Ward K, Goodman M. Cancer in transgender people: evidence and methodological considerations. Epidemiol Rev. 2017;39(1):93-107. https://doi.org/10.1093/epirev/mxw003
15. Deutsch MB, Radix A, Wesp L. Breast Cancer screening, management, and a review of case study literature in transgender populations. Semin Reprod Med. 2017;35(5):434-41. https://doi.org/10.1055/s-0037-1606103
16. Stone JP, Hartley RL, Temple-Oberle C. Breast cancer in transgender patients: A systematic review. Part 2: Female to Male. Eur J Surg Oncol. 2018;44(10):1463-8. https://doi.org/10.1016/j.ejso.2018.06.021
17. Price S, McManus J, Barrett J. The transgender population: improving awareness for gynaecologists and their role in the provision of care. Obstet Gynaecol. 2019;21(1):11-20. https://doi.org/10.1111/tog.12521
18. Nikolić D, Granić M, Ivanović N, Zdravković D, Nikolić A, Stanimirović V, et al. Breast cancer and its impact in male transsexuals. Breast Cancer Res Treat. 2018;171(3):565-9. https://doi.org/10.1007/s10549-018-4875-y
19. Sonnenblick EB, Shah AD, Goldstein Z, Reisman T. Breast imaging of transgender individuals: a review. current radiology reports. 2018;6(1):1-12. https://doi.org/10.1007/s40134-018-0260-1
20. Chotai N, Tang S, Lim H, Lu S. Breast cancer in a female to male transgender patient 20 years post-mastectomy: issues to consider. Breast J. 2019;25(6):1066-70. https://doi.org/10.1111/tbj.13417
21. Schmidt M, Ditrio L, Shute B, Luciano D. Surgical management and gynecologic care of the transgender patient. Curr Opin Obstet. Ginecol. 2019;31(4):228-34. https://doi.org/10.1097/GCO.0000000000000553
22. Parikh U, Mausner E, Chhor CM, Gao Y, Karrington I, Heller SL. Breast imaging in transgender patients: what the radiologist should know. Radiographics. 2020;40(1):13-27. https://doi.org/10.1148/rg.2020190044
23. Schmidt E, Rizzolo D. Disease screening and prevention for transgender and gender-diverse adults. JAAPA. 2017;30(10):11-6. https://doi.org/10.1097/01.JAA.0000524709.87224.57
24. Stewart T, Lee YA, Damiano EA. Do transgender and gender diverse individuals receive adequate gynecologic care? An analysis of a rural academic center. Transgend Health. 2020;5(1):50-8. https://doi.org/10.1089/trgh.2019.0037
25. Li JZ, Tu HYV, Avram R, Pinthus J, Bordeleau L, Hodgson N. Cancer prevention and screening in a BRCA2-positive male to female transgender patient. Breast J. 2018;24(6):1112-3. https://doi.org/10.1111/tbj.13096
26. Eismann J, Heng YJ, Fleischmann-Rose K, Tobias AM, Phillips J, Wulf GM, et al. Interdisciplinary management of transgender individuals at risk for breast cancer: case reports and review of the literature. Clin Breast Cancer. 2019;19(1):e12-9. https://doi.org/10.1016/j.clbc.2018.11.007

27. Kiely D. Transgender patient screening: breast cancer risk assessment and screening recommendations. Clin J Oncol Nurs. 2017;21(3):E67-70. https://doi.org/10.1188/17.CJON.E67-E70

28. Patel JM, Dolitsky S, Bachman GA, Meritens AB. Gynecologic cancer screening in the transgender male population and its current challenges. Maturitas. 2019;129:40-4. https://doi.org/10.1016/j.maturitas.2019.08.009

29. Blok CJ, Wiepjes CM, Nota NM, van Engelen K, Adank MA, Dreijerink KM, et. al. Breast cancer risk in transgender people receiving hormone treatment: nationwide cohort study in the Netherlands British Medical Journal. BMJ. 2019; 365:l1652. https://doi.org/10.1136/bmj.l1652

30. Narayan A, Lebron-Zapata L, Morris E. Breast cancer screening in transgender patients: findings from the 2014 BRFSS survey. Breast Cancer Res Treat. 2017;166(3):875-9. https://doi.org/10.1007/s10549-017-4461-8

31. Hartley RL, Stone JP, Temple-Oberle C. Breast cancer in transgender patients: a systematic review. Part 1: male to female. Eur J Surg Oncol. 2018;44(10):1455-62. https://doi.org/10.1016/j.ejso.2018.06.035

32. Pivo S, Montes J, Schwartz S, Chun J, Kiely D, Hazen A, et al. Breast cancer risk assessment and screening in transgender patients. Clin Breast Cancer. 2017;17(5):e225-7. https://doi.org/10.1016/j.clbc.2016.08.003

33. Kiran T, Davie S, Singh D, Hranilovic S, Pinto AD, Abramovich A, et al. Cancer screening rates among transgender adults: cross-sectional analysis of primary care data. Can Fam Physician. 2019;65(1):e30-7. PMID: 30674526

34. Sterling J, Garcia MM. Cancer screening in the transgender population: a review of current guidelines, best practices, and a proposed care model. Transl Androl Urol. 2020;9(6):2771-85. https://doi.org/10.21037/tau-20-954

35. Labanca T, Mañero I, Pannunzio M. Transgender patients: considerations for routine gynecologic care and cancer screening. Int J Gynecol Cancer. 2020;30(12):1990-6. https://doi.org/10.1136/ijgc-2020-001860

36. Fledderus AC, Gout HA, Ogilvie AC, van Loenen DKG. Breast malignancy in female-to-male transsexuals: systematic review, case report, and recommendations for screening. Breast. 2020;53:92-100. https://doi.org/10.1016/j.breast.2020.06.008

37. Brown GR. Breast cancer in transgender veterans: a ten-case series. LGBT Health. 2015;2(1):77-80. https://doi.org/10.1089/lgbt.2014.0123

38. Donati CA, Nagelberg A. Screening mamário em pacientes transgénero bajo tratamento hormonal cruzado (THC). Situación actual y controvérsias. Rev Argent Mastología. 2019;38(137):116-32.

This is an open access article distributed under the terms of the Creative Commons license.