

PRIMARY BREAST LYMPHOMA PRESENTING AS LOCALLY ADVANCED BREAST CANCER: A CASE REPORT

Linfoma primário apresentando-se como um câncer de mama localmente avançado: relato de caso

Rebeca Neves Heinzen^{1*}, Felipe Eduardo Martins de Andrade¹, Fernando Nalesso Aguiar²,
Fábio Arruda de Oliveira¹, Alfredo Carlos Simões Dornellas de Barros¹

ABSTRACT

Hematopoietic diseases can be found in the breast and mimic a mammary neoplasm, such as leukemia and/or lymphoma. Although lymphomas are considered lymph node tumors, 25-40% have extranodal sites. Primary lymphomas of the breast represent 0.1-0.5% of all breast neoplasms and may have primary or secondary origin. Primary lymphomas normally start in the breast without involvement of other sites. The diagnosis is made through physical and pathological examination. We report a 77-year-old female who had a locally advanced mass in the right breast associated with inflammatory signs and symptoms and with palpable axillary lymph nodes. The imaging tests were non-specific and didn't help the diagnosis. The pathology report revealed a diffuse, B-cell lymphoma infiltrating the breast (lymphoma non-Hodgkin's). Due to the rarity of the case, and the unknown pathogenesis systemic chemotherapy with CHOP (cyclophosphamide, doxorubicin, vincristine and prednisone) regime were performed. The use of rituximab, as well as radiotherapy, remain controversial in the literature, but for some authors the radiotherapy is indicated with a total dose of 30 to 45 Gy. Our patient performed radiotherapy of the breast and axilla. Because of total remission of the disease, it was not necessary complementary treatment or breast surgery.

KEYWORDS: Lymphoma; Breast cancer; Non-Hodgkin lymphoma.

RESUMO

Doenças hematopoiéticas podem ser encontradas na mama e simular uma neoplasia mamária, como leucemia e/ou linfoma. Apesar de os linfomas serem considerados tumores linfonodais, 25-40% acometem sítios extranodais, sendo um deles a mama. Os linfomas primários da mama representam 0,1-0,5% de todas as neoplasias da mama. Podem ter origem primária ou secundária. Os primários normalmente iniciam-se na mama sem acometimento de outros sítios linfonodais. O diagnóstico é feito através do exame físico e anatomopatológico. Relatamos um caso de uma paciente, idosa, de 77 anos, que compareceu em nosso serviço com uma massa progressiva envolvendo toda a mama direita, ulcerada e associada a sinais e sintomas inflamatórios com linfonodos axilares palpáveis. Os exames de imagem foram inespecíficos e não ajudaram no diagnóstico, não tendo sido recomendados para o rastreamento dessa neoplasia. O exame anatomopatológico revelou um linfoma de células B difuso infiltrando a mama (linfoma não Hodgkin). Devido à raridade do caso, a etiopatogenia é desconhecida, e o tratamento foi realizado com os esquemas quimioterápicos para linfoma segundo o consenso para linfomas de células B, sendo a base o tratamento com antraciclina. A paciente realizou seis ciclos de CHOP (ciclofosfamida, doxorubicina, vincristina e prednisona), com a regressão total da lesão. O uso do rituximabe, bem como a radioterapia, permanecem controversos na literatura, mas a radioterapia é indicada por alguns autores na dose de 30 a 45 Gy. Nossa paciente realizou radioterapia da mama e da axila com ausência de remissão da doença, não tendo sido necessário tratamento complementar ou cirurgia da mama.

PALAVRAS-CHAVE: Linfoma; Neoplasias da mama; Linfoma não Hodgkin.

Study carried out at the Instituto de Responsabilidade Social of Hospital Sírio Libanês – São Paulo (SP), Brazil.

¹Hospital Sírio-Libanês – São Paulo (SP), Brasil.

²Universidade de São Paulo – São Paulo (SP), Brasil.

*Corresponding author: rebecanh@gmail.com

Conflict of interests: nothing to declare

Received on: 12/19/2016. Accepted on: 05/30/2017

INTRODUCTION

Hematopoietic diseases can be found in breast and mimic breast cancer, like leukemia and/or lymphoma. Although lymphomas are considered lymph node tumors, 25–40% involve extranodal sites. By definition, extranodal diseases refer to any lymph node involvement of the lymphatic system in other tissues, such as the central nervous system, Waldeyer ring, lungs, bones, skin and stomach¹⁻³. We report a case of breast lymphoma presenting as a locally advanced breast cancer.

CASE DESCRIPTION

We describe a 77-year-old female patient, without comorbidities. She was referred to our hospital due to a progressive lump growth in the right breast noticed four months before. The contralateral mammography (left breast) showed a category BI-RADS 2. The patient had no family history of cancer, except for an aunt who died of intestinal cancer. Physical examination revealed a large mass involving the entire right breast. The mass was ulcerated and associated with inflammatory signs and palpable ipsilateral axillary lymph node (cT4bN2) (Figure 1). Histopathologic investigation with core biopsy was performed. The pathology findings confirmed the diagnosis as diffuse B-cell lymphoma infiltrating the breast tissue (diffuse non-Hodgkin lymphoma) (Figure 2). The patient had a Karnofsky performance status of 90 and an ECOG 1. The treatment recommended was chemotherapy with six cycles of CHOP (cyclophosphamide, hydroxy doxorubicin, vincristine, Prednisone). A complete clinical response

with regression of the mammary lesion after the fifth cycle was observed. The treatment was complemented with breast radiotherapy of the right axilla. Currently, the patient is under regular monitoring, without signs of recurrence or progression of the disease as of her last visit (Figure 3).

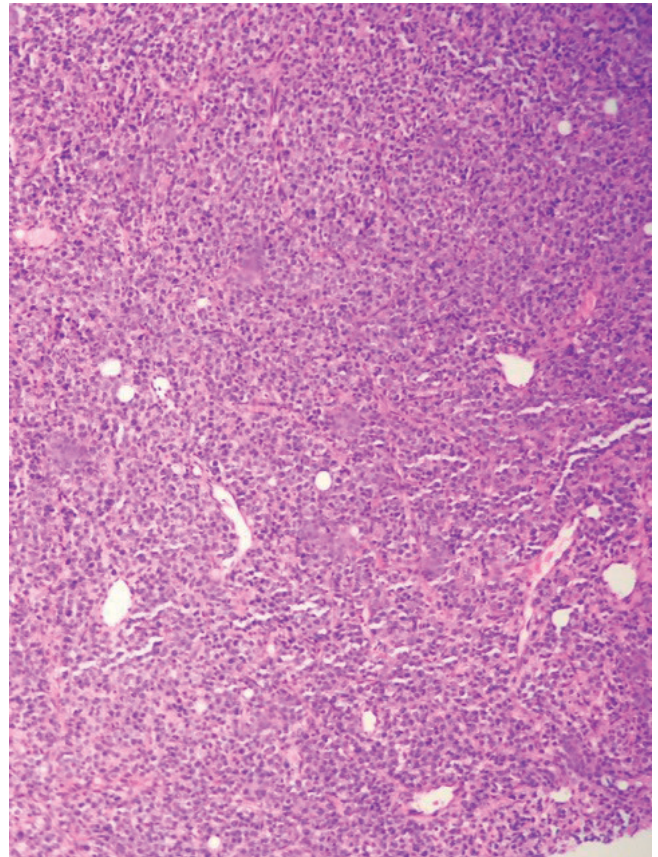


Figure 2. Diffuse B-cell lymphoma.

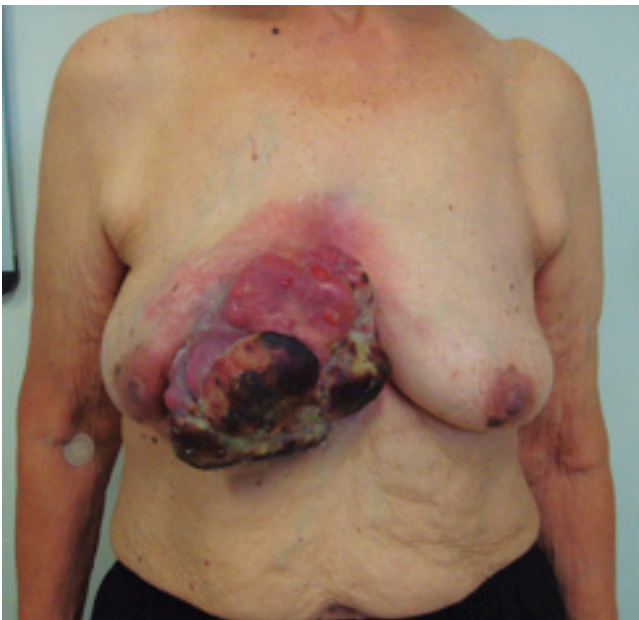

Figure 1. Large mass involving the entire right breast.

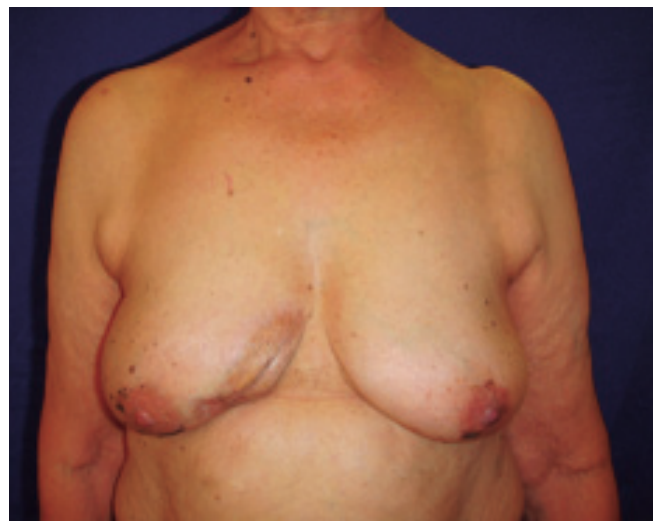

Figure 3. Resolution after chemotherapy.

DISCUSSION

Primary breast lymphomas are rare tumors, accounting for 0.85 to 2.20% of all extranodal lymphomas and 0.1 to 0.5% of all breast tumors. The World Health Organization (WHO) subdivides breast lymphomas into large cell lymphoma, Burkitt's lymphoma, and mucosa-associated lymphoid tissue (MALT) follicular lymphoma. Their origin may be primary or secondary and the distinction is often very difficult. The primary tumor is first manifested in the breast, without history or evidence of lymph node disease elsewhere, except in the ipsilateral axilla and supraclavicular lymph nodes. Primary breast lymphomas are usually B-cell non-Hodgkin lymphomas, but there are reports of some forms of T-cell lymphoma, common in Asia^{4,5}. This pathology was first described in 1972 by Liao and Wiseman⁶. They proposed four diagnostic criteria that are still used:

1. Presence of lymphoma and breast tissue, very close anatomically.
2. Previous diagnosis of lymphoma.
3. Absence of another disseminated disease.
4. Lack of adequate and quality histopathological sample^{1,2,6}.

Due to its rarity, the natural history of the disease and pathogenesis remains unknown. As there are few reports of men with this involvement, some hypotheses suggest the role of sex hormones². The natural history of breast lymphoma is known to be different from other extranodal lymphomas, due to its rapid progression and poor prognosis¹. The diagnosis is made by clinical examination and pathology, and the disease usually occurs in women in their 50s or 60s⁴. The most common symptom is a lump or a palpable, unilateral and painless mass in the breast. Although rare, there are some reports of bilateral lymphomas⁷. Other diagnoses are made through incidental findings in mammography screening or computed tomography (CT) scans^{1,4}. Less frequent symptoms are shrinking or papillary flow, thinning of the skin and swelling, simulating an inflammatory carcinoma and B symptoms (fever, weight loss and sweating), which are more common in patients with secondary origin^{1,2,4}. Aviv et al. showed that only 5% of 906 patients studied had B symptoms, and suggest that the absence of these symptoms may be because the vast majority of patients are pre-selected for diagnostic criteria². Imaging tests are nonspecific and do not provide a diagnosis. In mammography images, the lesion can be present as a circumscribed lesion⁵ without calcifications or a desmoplastic reaction

and on ultrasound, usually as a hypoechoic mass^{8,9}. Glazebrook showed that half of all cases of breast lymphoma present an irregular mass with indistinct margins, a third circumscribed margin, four cases of breast asymmetry, and one case as an architectural distortion⁴. According to Domchek et al., a mammogram does not increase its detection rate¹⁰. Although there are few reports, magnetic resonance imaging (MRI) appears to have a role in establishing the extent of disease and response to therapy. Positron emission tomography (PET/CT) proved to be a good test for staging lymphoma, with sensitivity and specificity close to 100%. This technique is useful for evaluating therapeutic response, demonstrating residual metabolic activity of the tumor and areas of necrosis and fibrosis. It may be useful in female patients with dense breasts where mammography shows a dark mass^{1,4}. The patient is classified in stages for diagnostic criteria based on the staging for lymphomas (Ann Arbor classification). The Ann Arbor staging system is indicated by the tumor localization. Breast lymphoma comprises only stage I and II. This means that, when only one extra lymphatic site is involved, stage IE is indicated, or when lymph nodes with local extension extra lymphatic on the same side of the diaphragm are involved stage IIE is indicated. The letter E is used when the disease is extranodal. The distinction in staging is important because it entails a difference of 5 years survival, with a survival rate of 78-83% in the IE stage against 20-57% in stage IIE. Prognostic factors: Ann Arbor stage greater than IE, increased lactate dehydrogenase (DHL) and, according to some authors, tumor size greater than 4-5 cm². As a rare condition, most of the processing is carried out on the basis of trials to diffuse B-cell lymphomas, the main system based on treatments with anthracycline, the most common being the CHOP regimen (cyclophosphamide, hydroxy doxorubicin, vincristine, Prednisone). A few studies show that adding rituximab improves the effectiveness of treatment, therefore many authors recommend its use with a view to a greater chance of eradicating lymphoma and decreasing disease recurrence. Hosein et al. showed no impact on survival levels with rituximab^{2,4,5}. The role of radiotherapy is still controversial, but it is believed that it has a positive impact on the outcome. Most patients receiving radiation dose of 30 to 45 Gy. Jennings et al., in a meta-analysis, demonstrated that radical surgery has no benefit for this disease and should be performed only for diagnosis⁶.

REFERENCES

1. Bertagna F, Orlando E, Bosio G, Biasiotto G, Dognini L, Giubbini R. Primary breast non-Hodgkin lymphoma. A report of an unusual case. *Nucl Med Rev Cent East Eur*. 2012;15(2):149-52.
2. Aviv A, Tadmor T, Polliack A. Primary diffuse large B-cell lymphoma of the breast: looking at pathogenesis, clinical issues and therapeutic options. *Ann Oncol*. 2013;24(9):2236-44.
3. Glazebrook KN, Zingula S, Jones KN, Fazzio RT. Breast imaging findings in hematological malignancies. *Insights Imaging*. 2014;5(6):715-22.
4. Hosein PJ, Maragulia JC, Salzberg MP, Press OW, Habermann TM, Vose JM, et al. A multicenter study of primary breast diffuse large B-cell lymphoma in the rituximab era. *Br J Haematol*. 2014;165(3):358-63.

5. Joks M, My liwiec K, Lewandowski K. Primary breast lymphoma - a review of the literature and report of three cases. *Arch Med Sci.* 2011;7(1):27-33.
6. Liao KT, Wiseman C. Primary lymphoma of the breast. *Cancer.* 1972;29(6):1705-12.
7. Lokesh KN, Sathyanarayanan V, Lakshmaiah KC, Suresh TM, Babu KG, Lokanatha D. Primary breast diffuse large B cell lymphoma - report of 6 cases from South India with review of literature. *Indian J SurgOncol.* 2013;4(4):368-73.
8. Luo B, Huang J, Yan Z, Zhao W, Wang L. Clinical and prognostic analysis of 21 cases of primary breast lymphoma. *ZhonghuaXue Ye XueZaZhi.* 2015;36(4):277-81.
9. Jennings WC, Baker RS, Murray SS, Howard CA, Parker DE, Peabody LF, et al. Primary breast lymphoma: The role of mastectomy and the importance of lymph node status. *Ann Surg.* 2007;245(5):784-9.
10. Domchek SM, Hecht JL, Fleming MD, Pinkus GS, Canellos GP. Lymphomas of the breast: primary and secondary involvement. *Cancer.* 2002;94(1):6-13.